

# Salivary ultrasound

Dr T J Beale

Royal National Throat Nose & Ear  
and UCLH Hospitals London UK

Two main groups of patients with presenting symptoms of:

- Obstructive or chronic inflammatory symptoms (**salivary colic**)
- or a mass..... ? Salivary in origin

Some overlap between groups

# Salivary Colic Tips..... Always

- Take a brief **history** from the patient
  - "strange tasting saliva"
  - "swelling under tongue"
  - "swelling associated with meals"

## **Examine:**

- the floor of mouth with submandibular colic
- bimanual palpation if more proximal stone
- the swelling (what does it feel like?)

**why?**

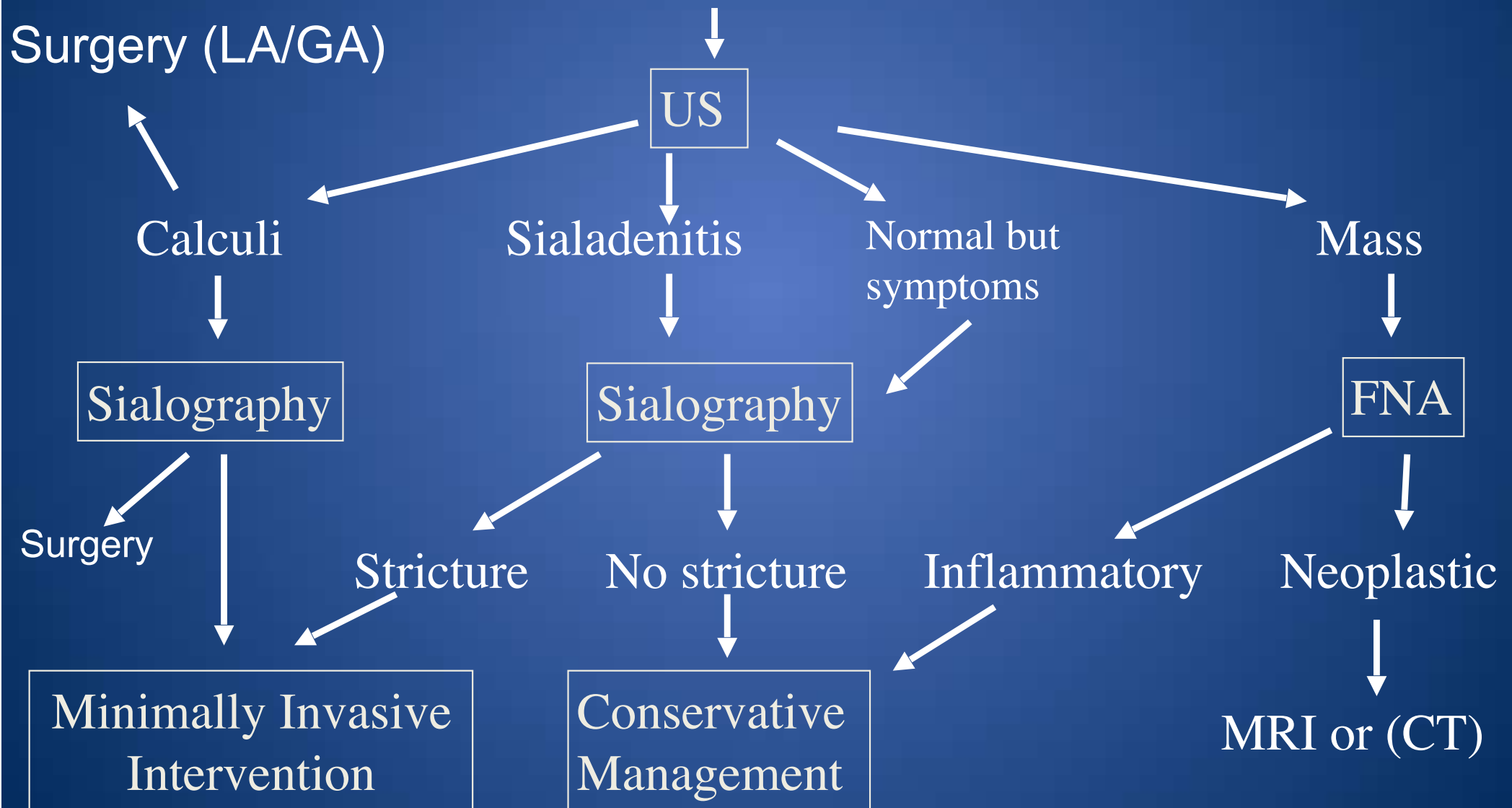
## **Examine:**

- the cheek with parotid swelling

**why?**

# Diagnostic Imaging Algorithm

## Salivary colic



# Why ultrasound initially?

- Usually gives the answer.. and quickly!
- Salivary glands superficial ... ideal
- Highest resolution
- Combined with FNA.....if mass seen
- **But operator dependent**

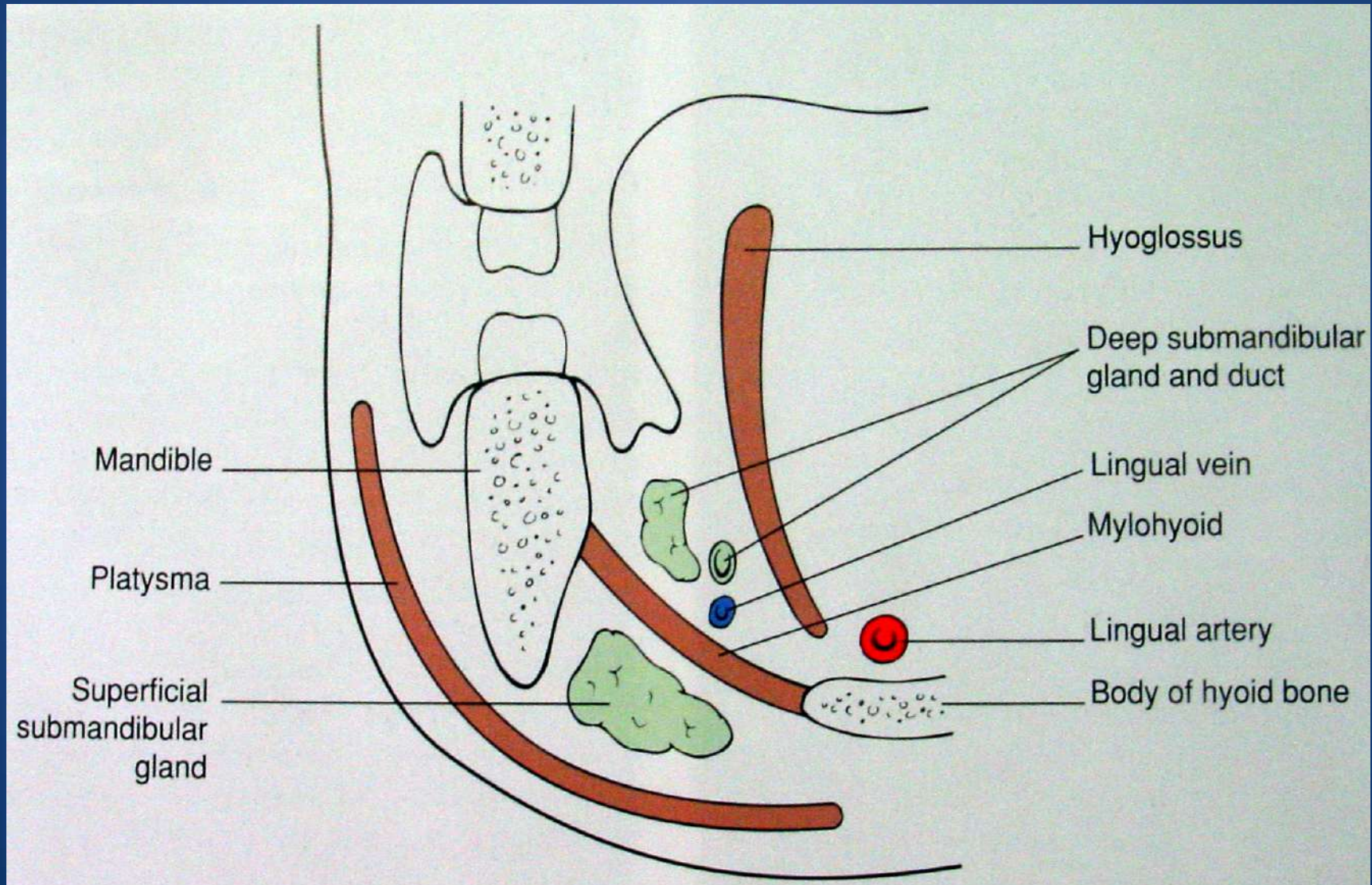
Start with **submandibular** salivary gland

- Why?

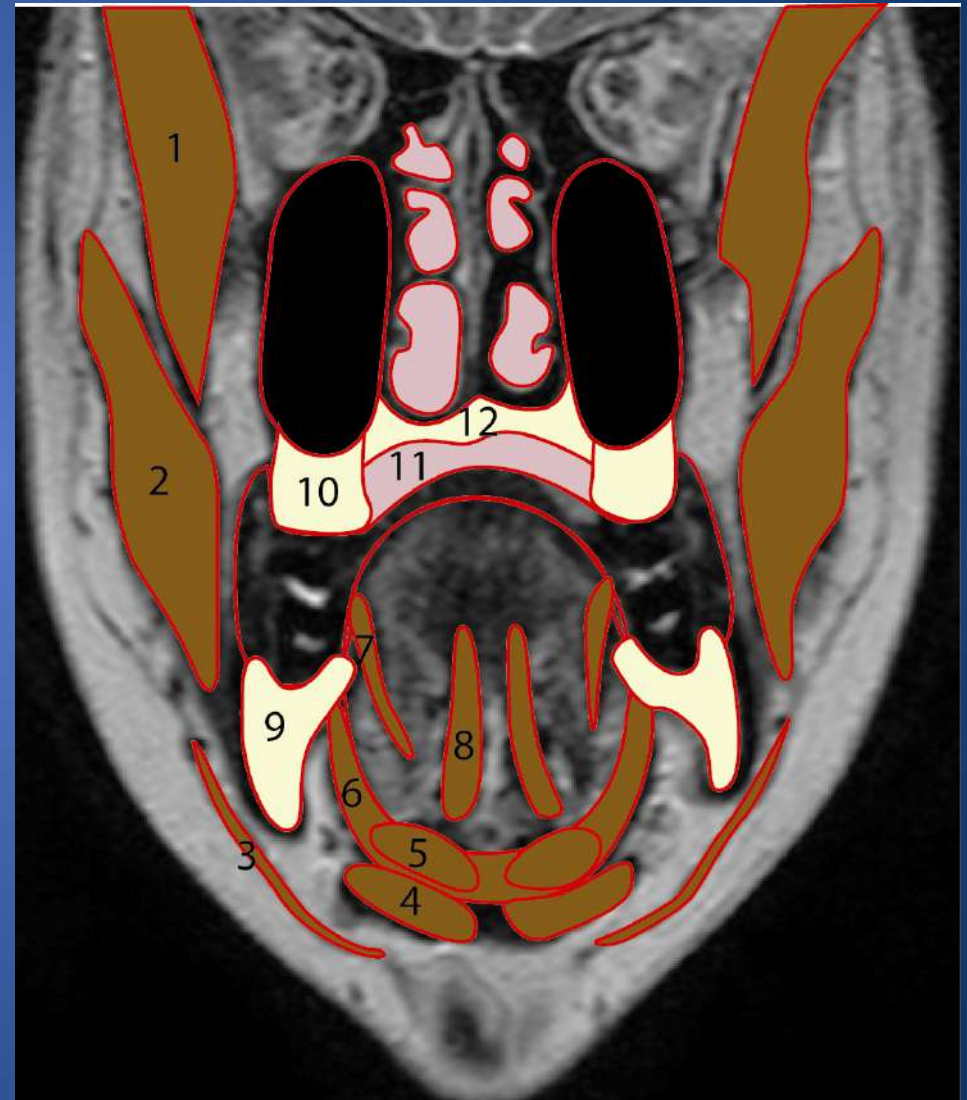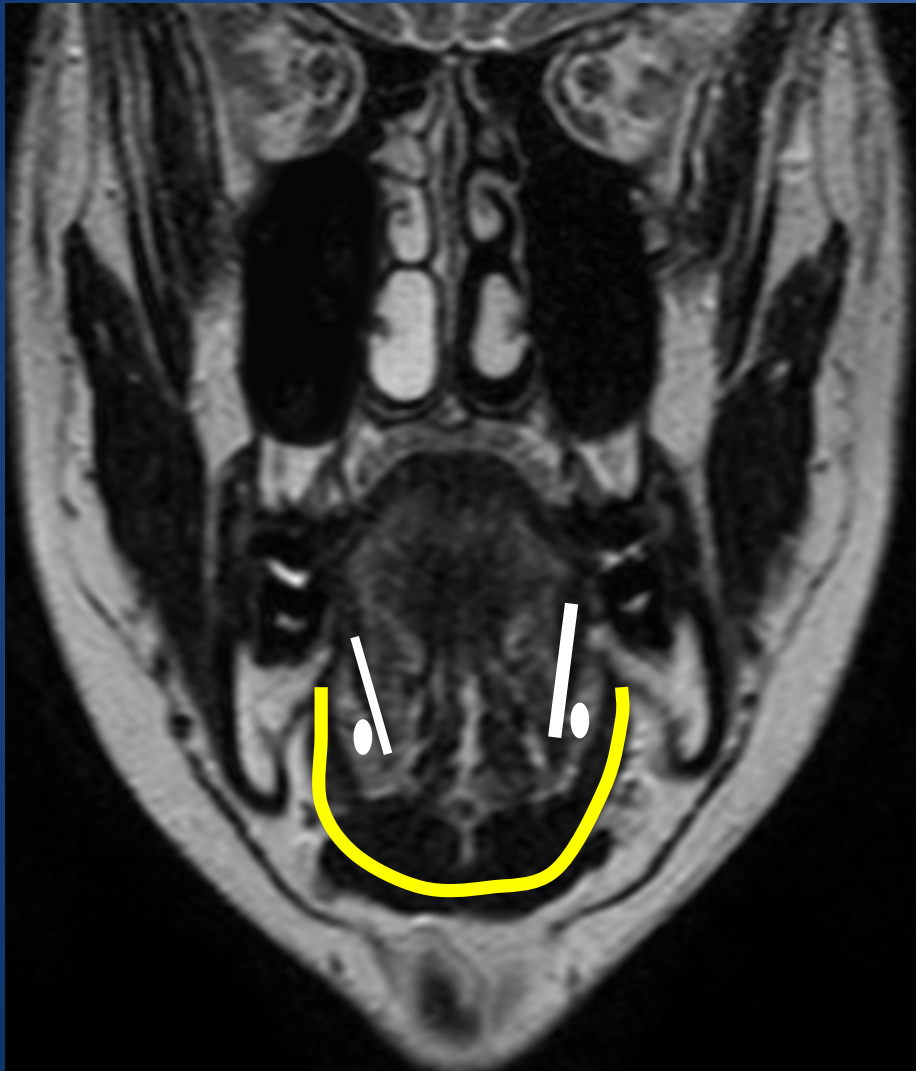# Submandibular Sialolithiasis

- **80%** of all salivary calculi.
- **85%** of calculi occur within the SM duct:
  - 30% ductal orifice
  - 20% mid-duct
  - 35% at hilum
- **80%** of SM calculi are radioopaque on plain film.
- **NB 25% of patients have multiple calculi!!**

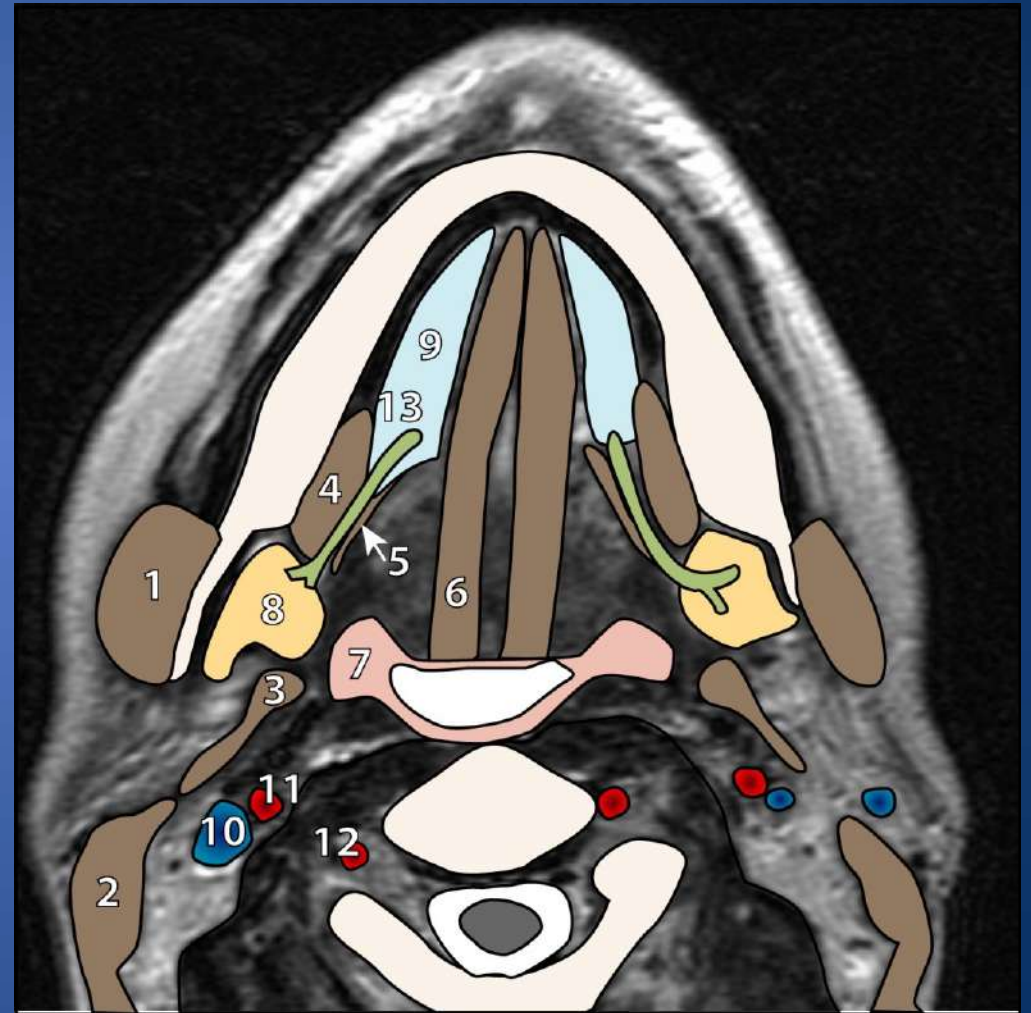
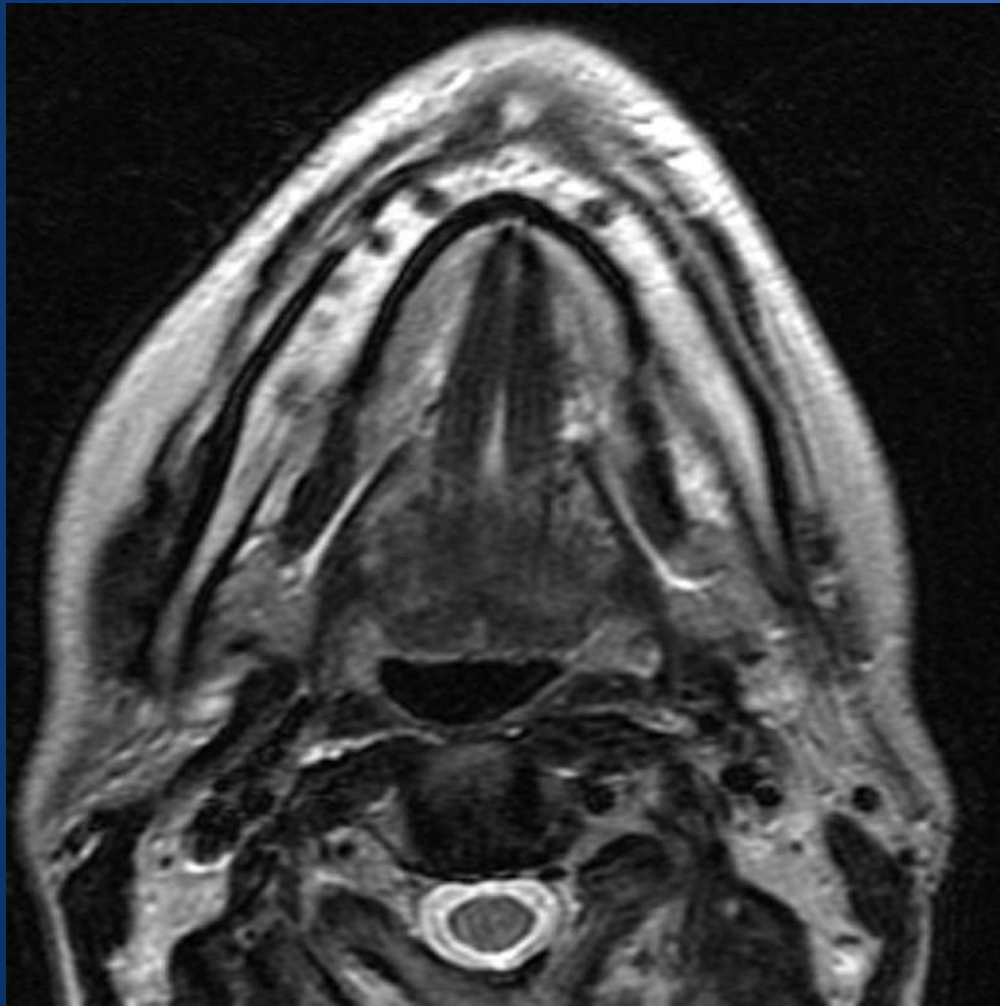
# Normal Anatomy of the Submandibular & Sublingual Spaces: Coronal Section



# MR Coronal Anatomy



# MR Submandibular Anatomy

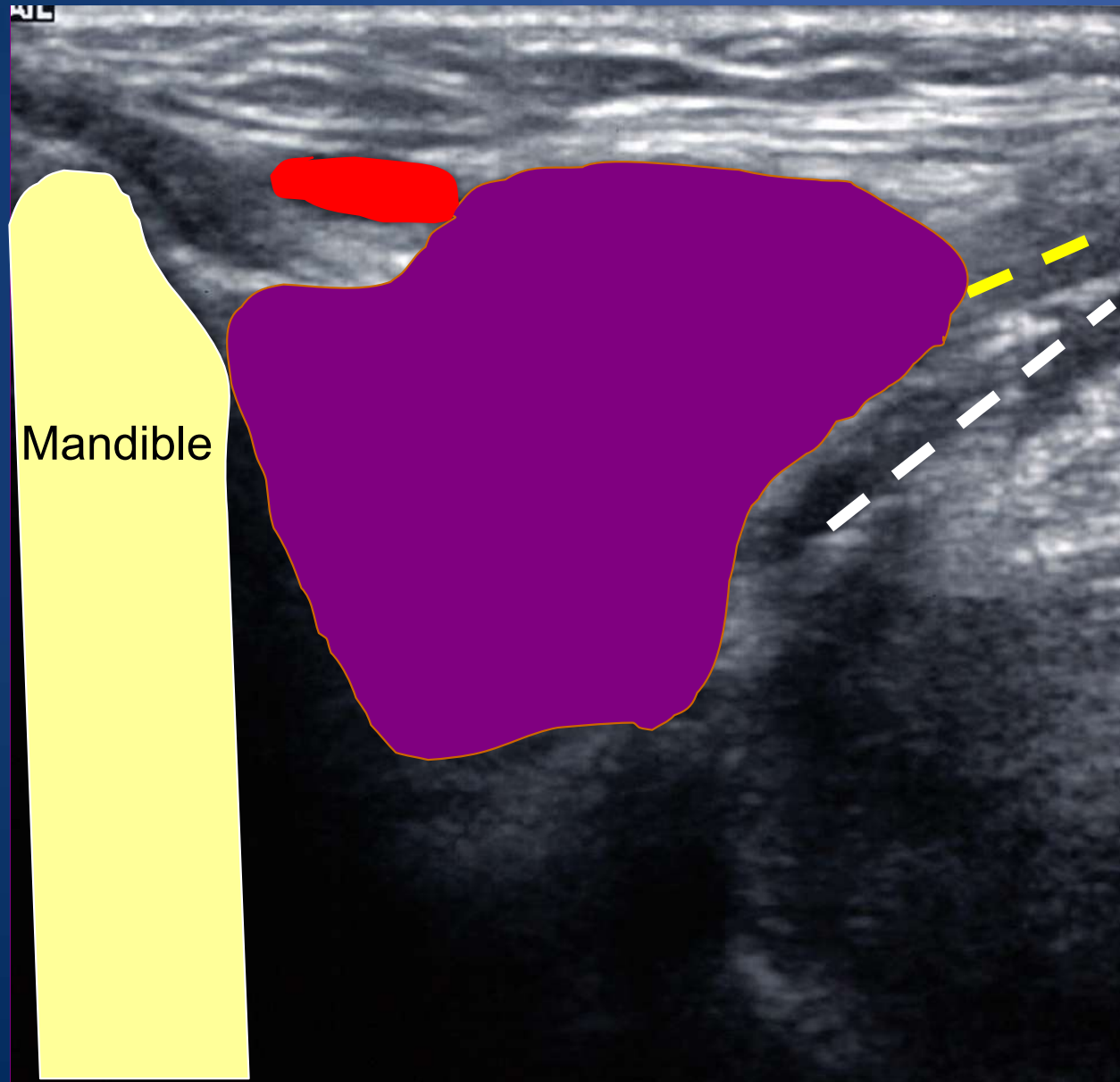


# Ultrasonography: SM Gland

## TECHNIQUE

- 10-15 MHz linear probe or 6MHz curvilinear
- Coronal section:  
Probe moved from hyoid bone to the submental area.
- Oblique sagittal section:-  
Probe **parallel** to ramus & body of mandible

# Coronal Ultrasound Anatomy: Submandibular Gland



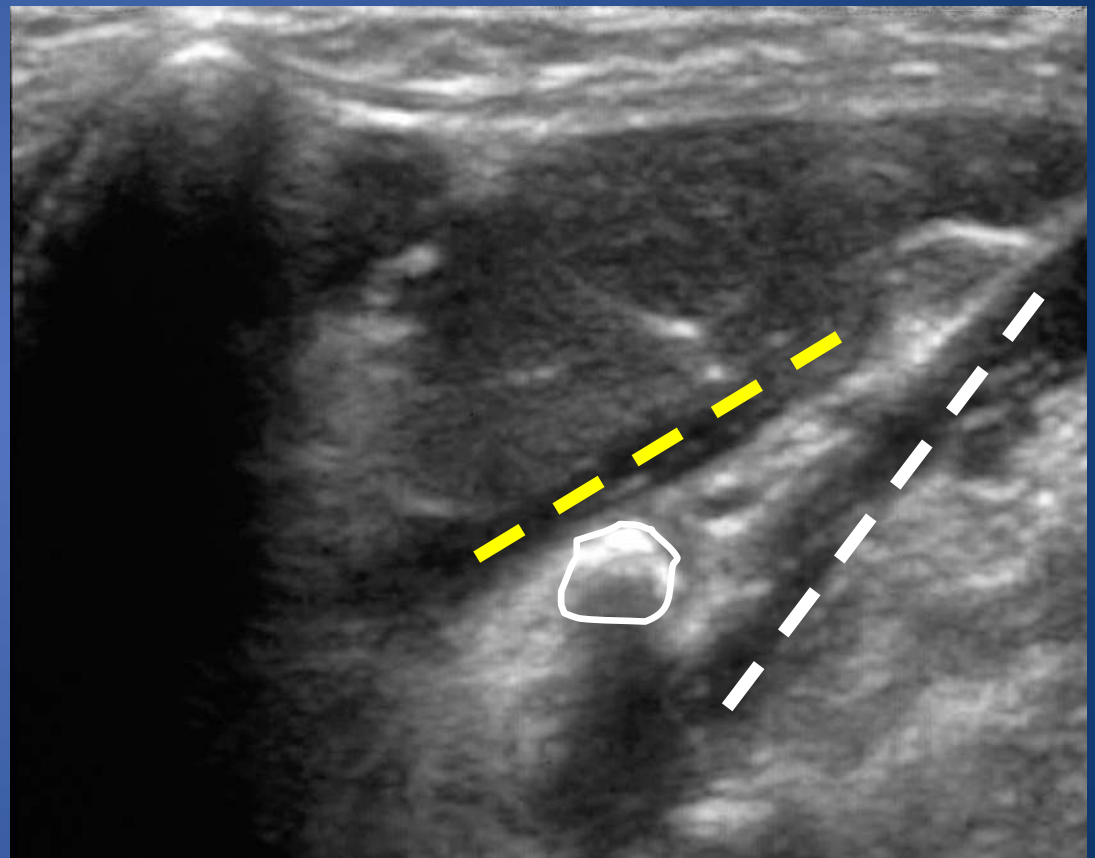
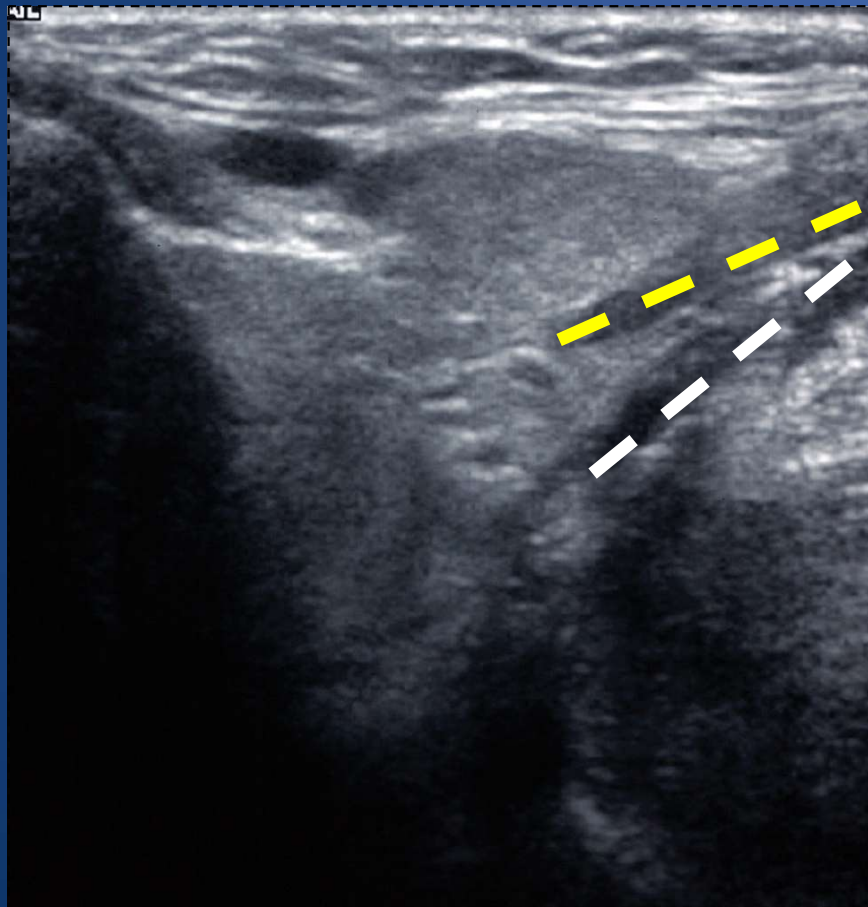
Coronal US image of a normal SM gland.

--- Mylohyoid muscle

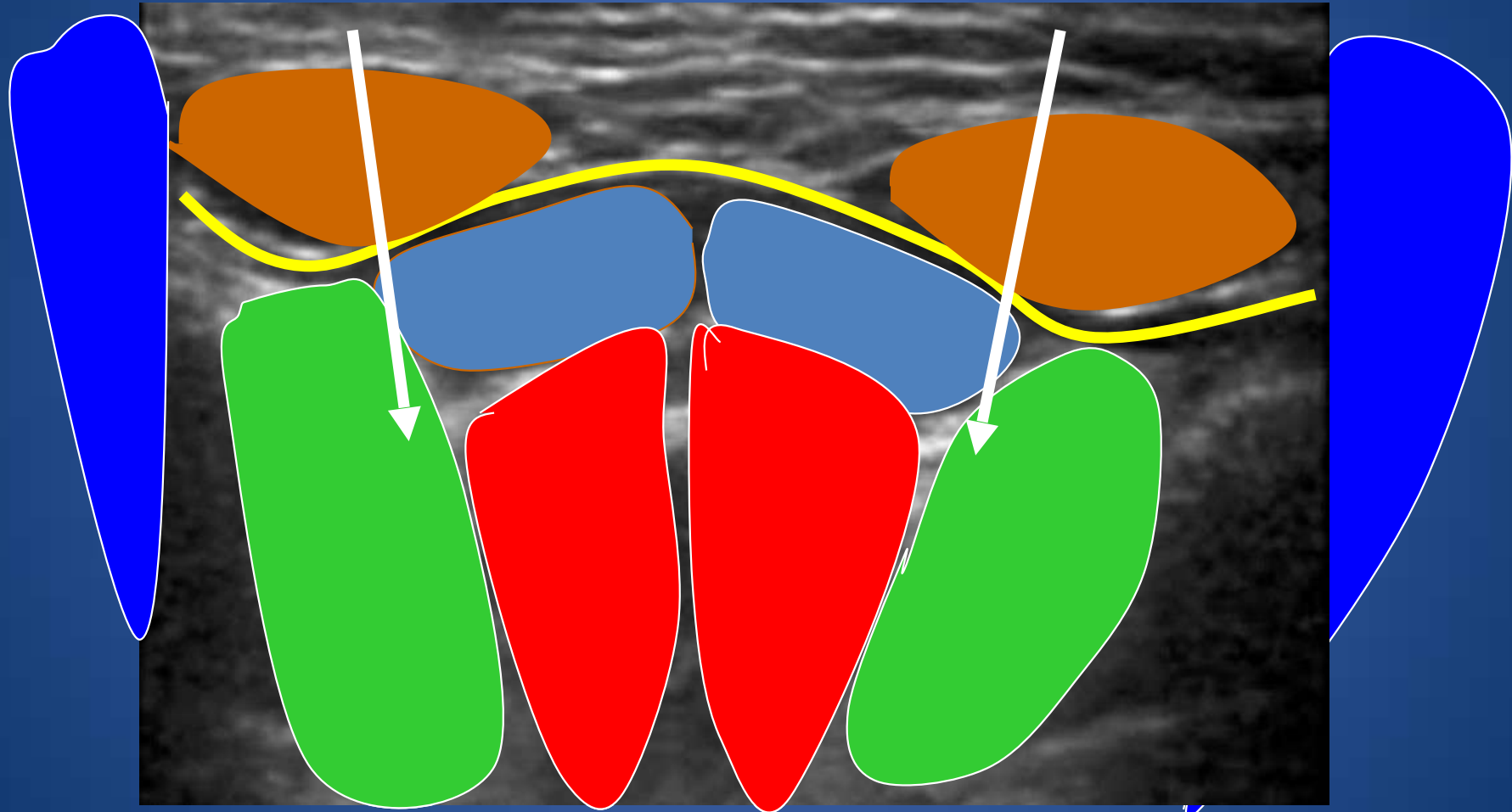
-- Hyoglossus muscle

○ Facial Artery

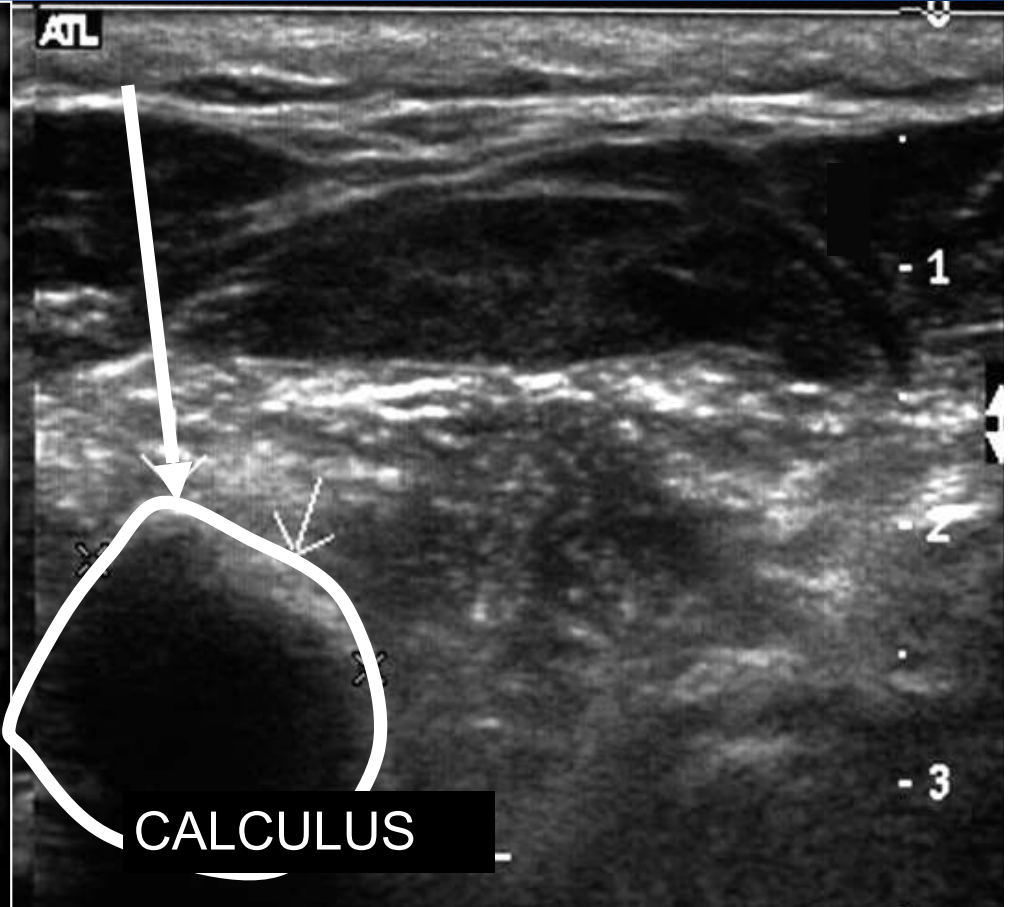
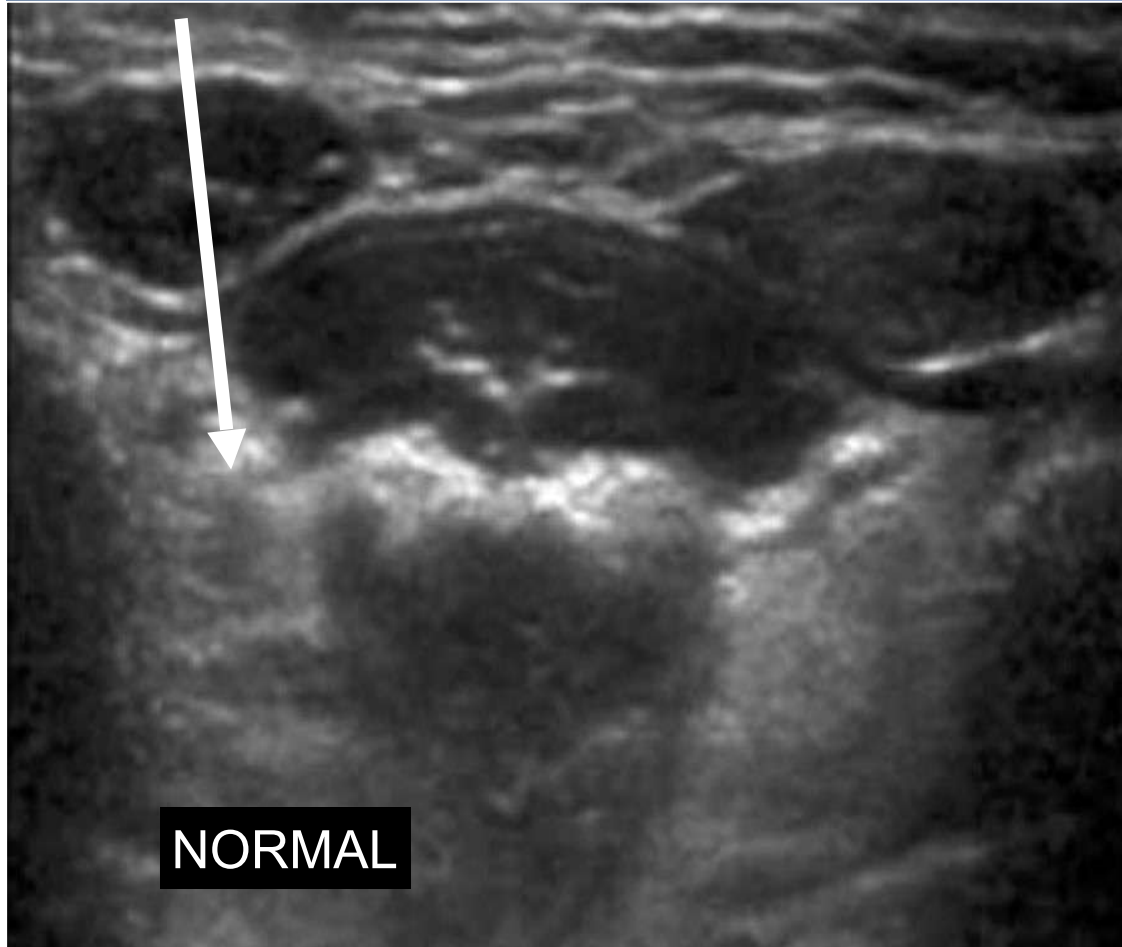
# Coronal Ultrasound Submandibular gland



# Coronal US Anatomy Floor of mouth



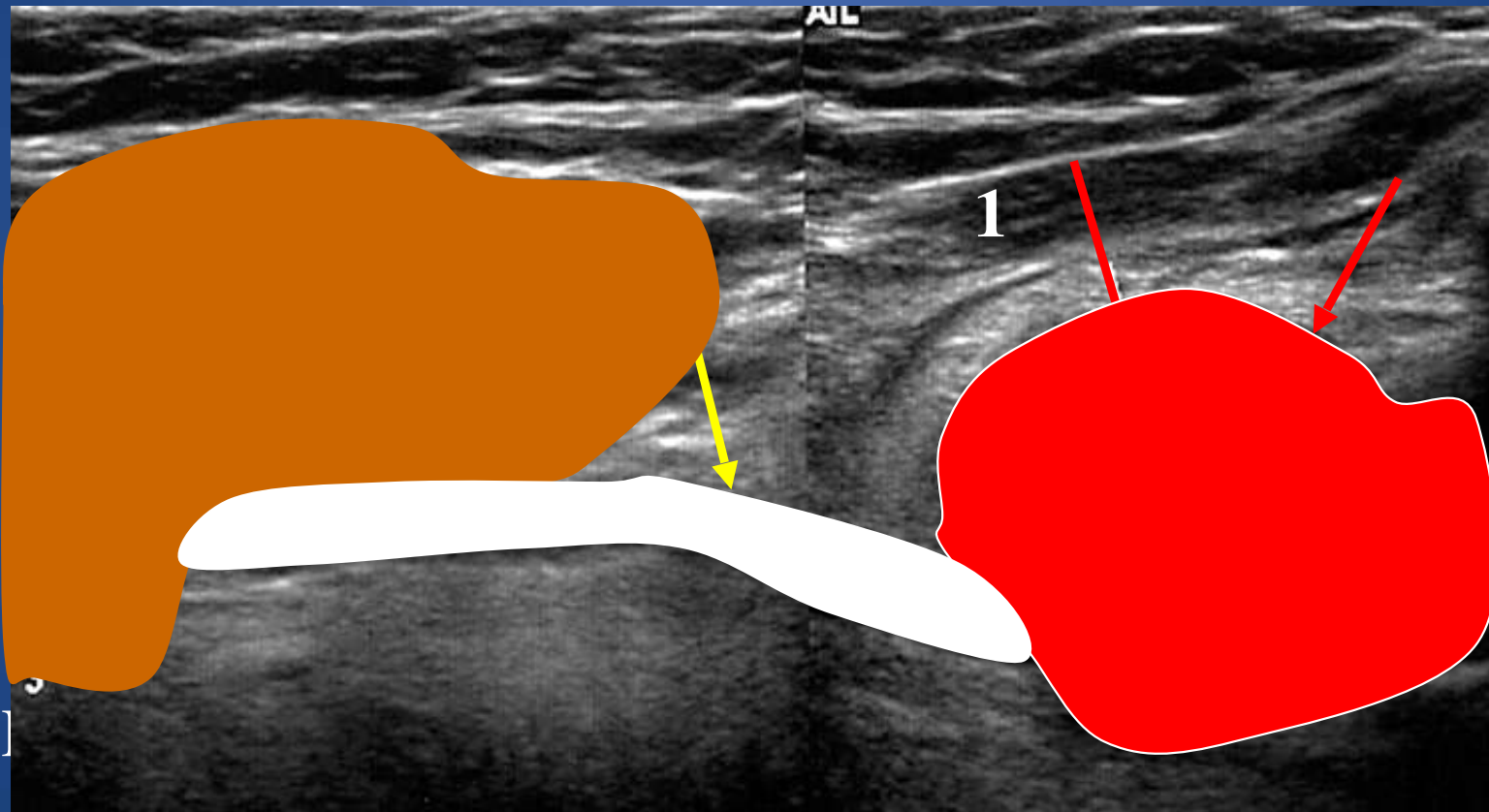
# Submandibular Calculi



# Diagnostic Pitfalls

- SMG obstruction may be due to a FOM carcinoma or malignancy of the sublingual gland.
- 25% of patients have multiple calculi. Examine whole ductal system and the contralateral side.
- The lingual vein may be mistaken for a distended SM duct

# Pitfall: Obstruction of SM duct by Tumour of Sublingual Gland



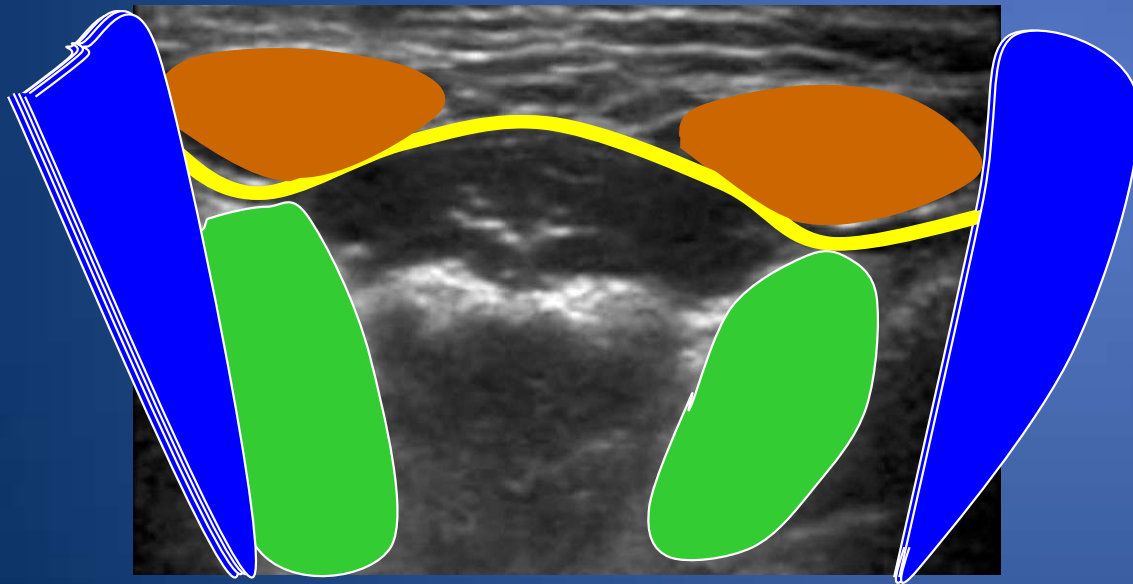
→ Dilated SM duct

1= Mylohyoid muscle

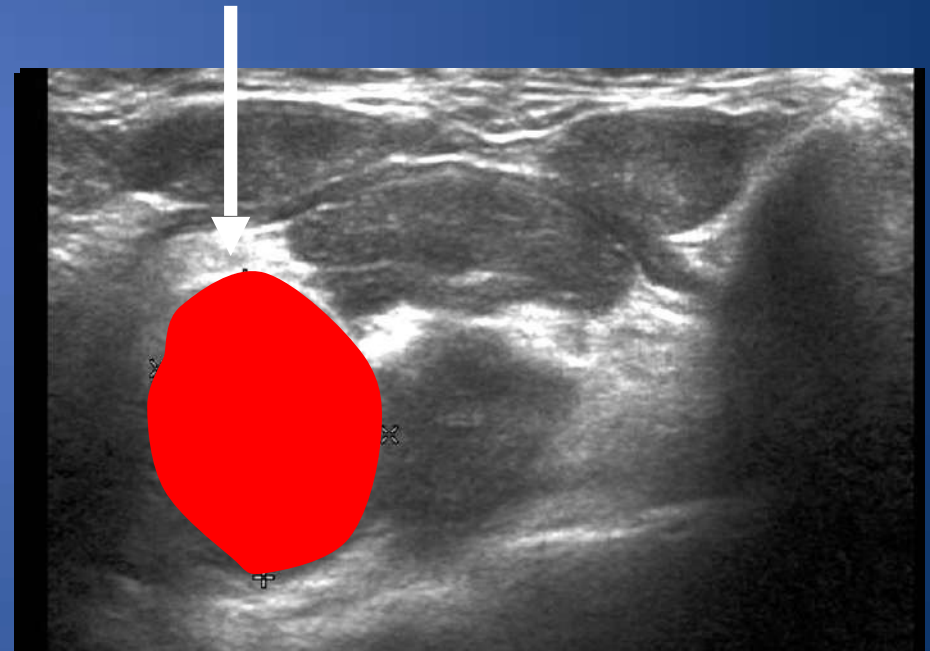
→ Adenoid cystic carcinoma of sublingual gland

# Coronal floor of mouth

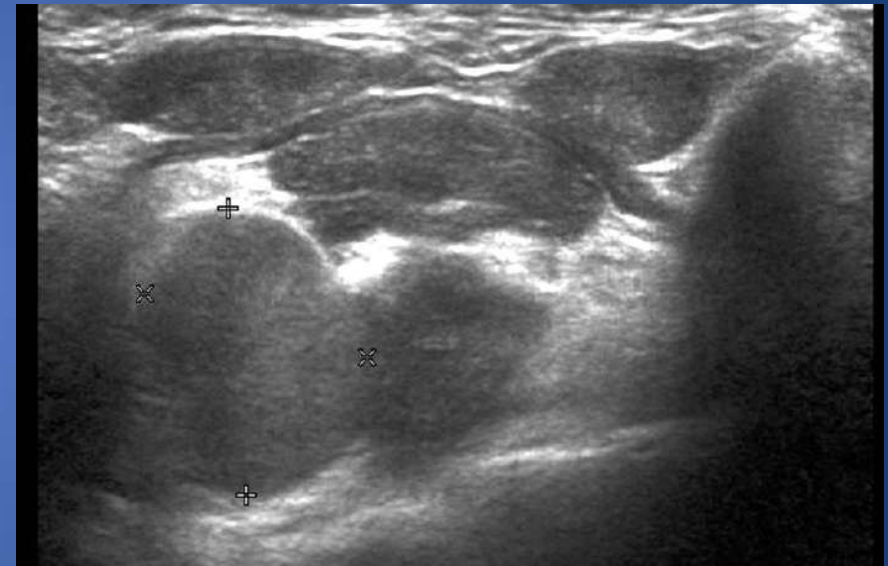
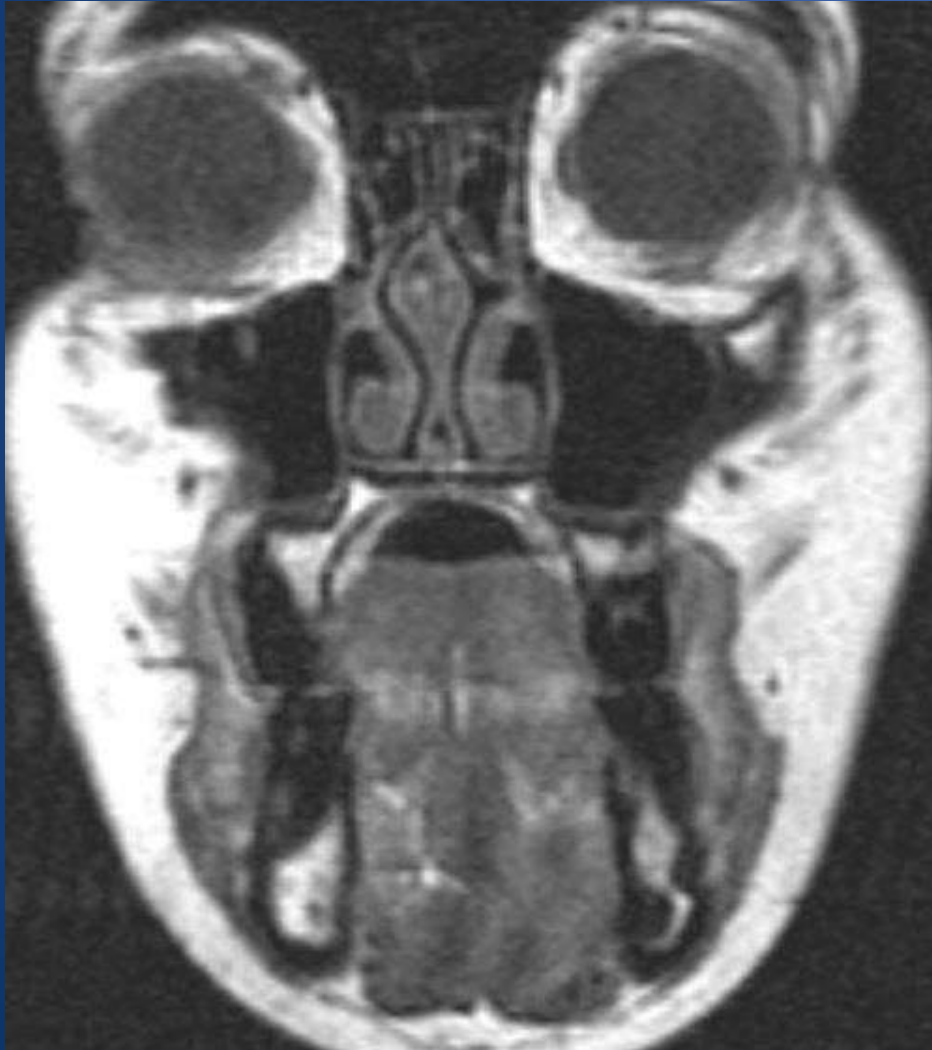Normal



Tumour



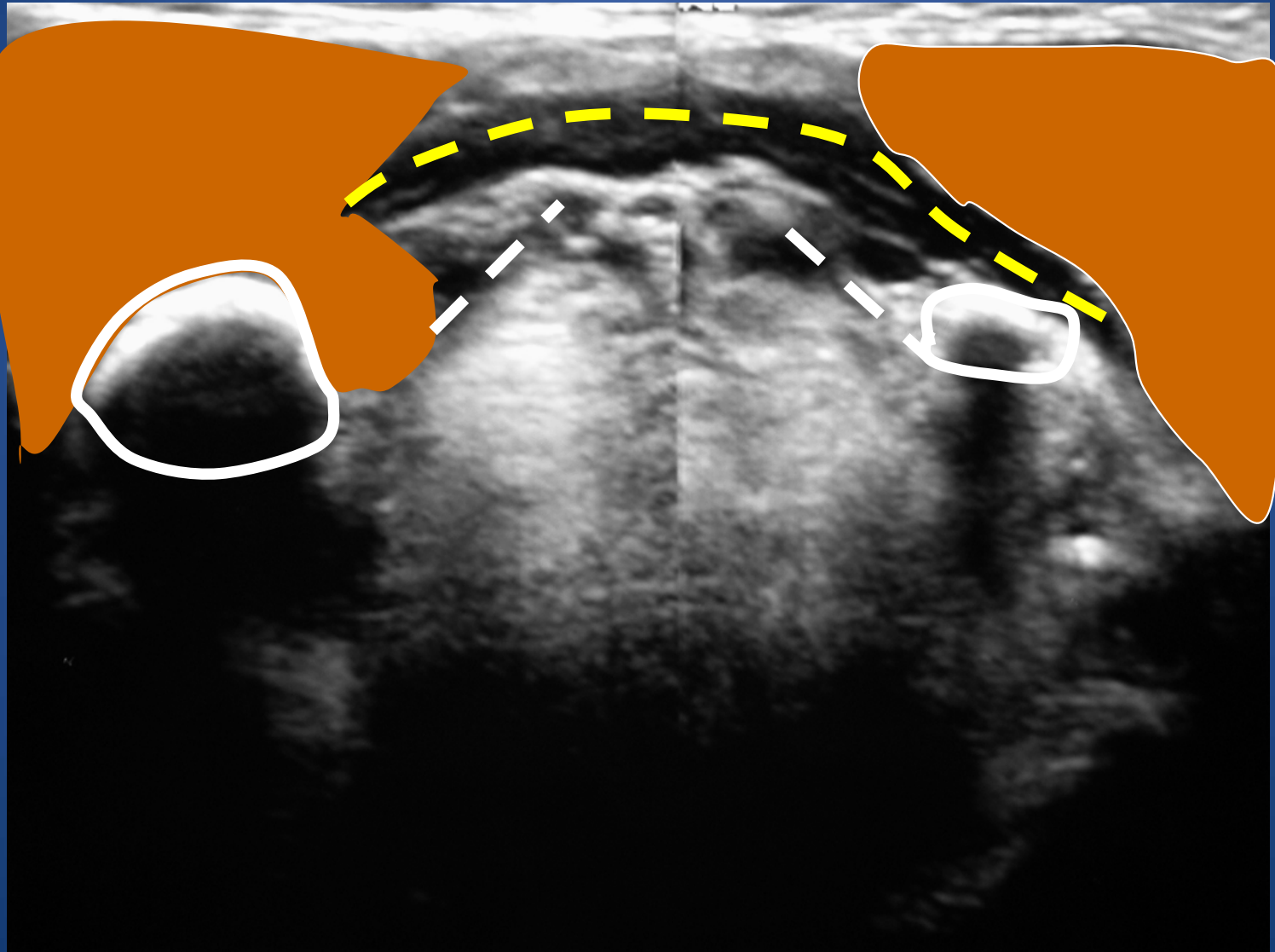
# Sublingual Adenoid cystic (ACC)



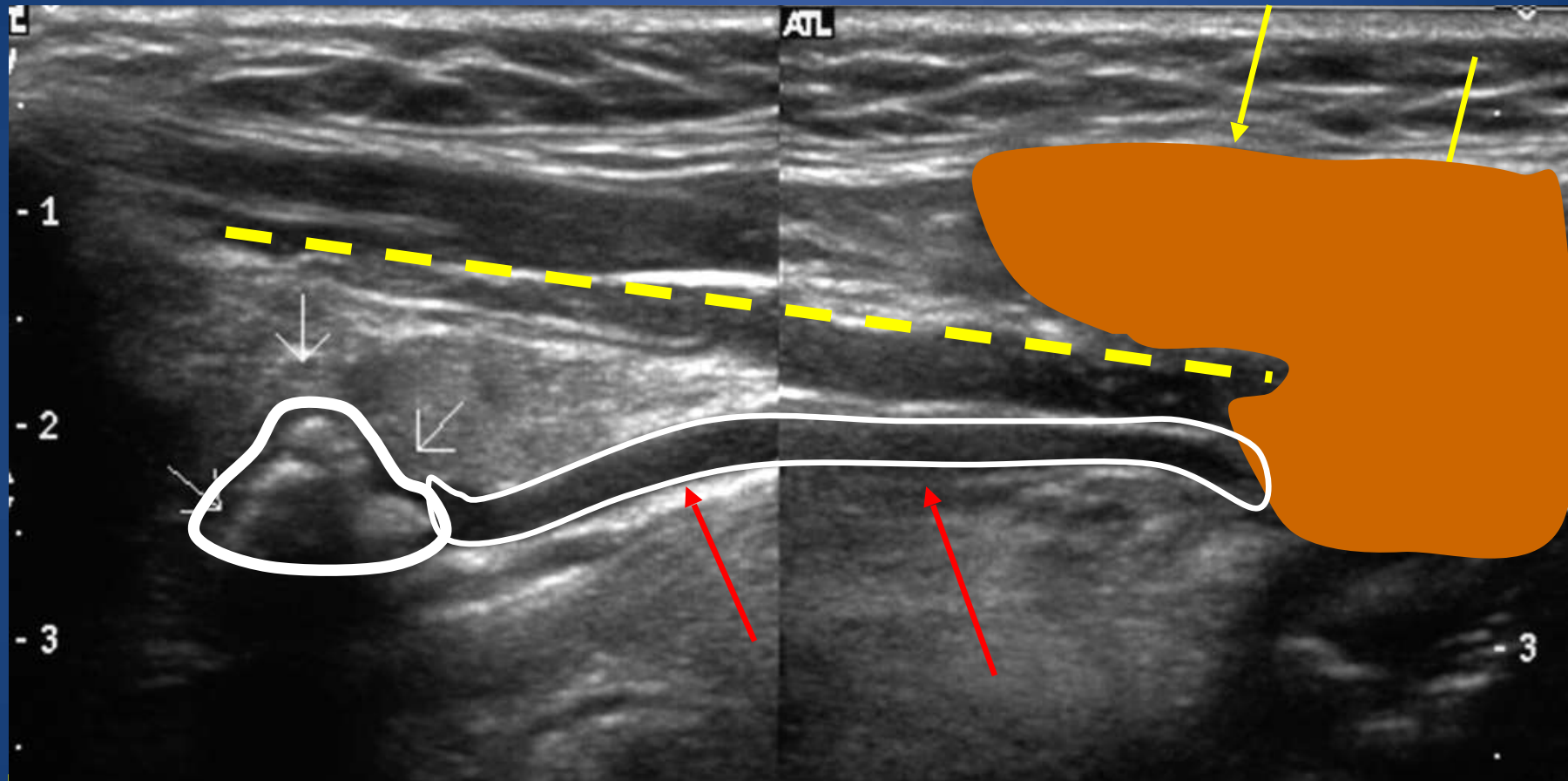
# Diagnostic Pitfalls

- SMG obstruction may be due to a FOM carcinoma or malignancy of the sublingual gland.
- **25% of patients have multiple calculi. Examine whole ductal system and the contralateral side.**
- The lingual vein may be mistaken for a distended SM duct

# Pitfall :Bilateral calculi Coronal US SMG hilar



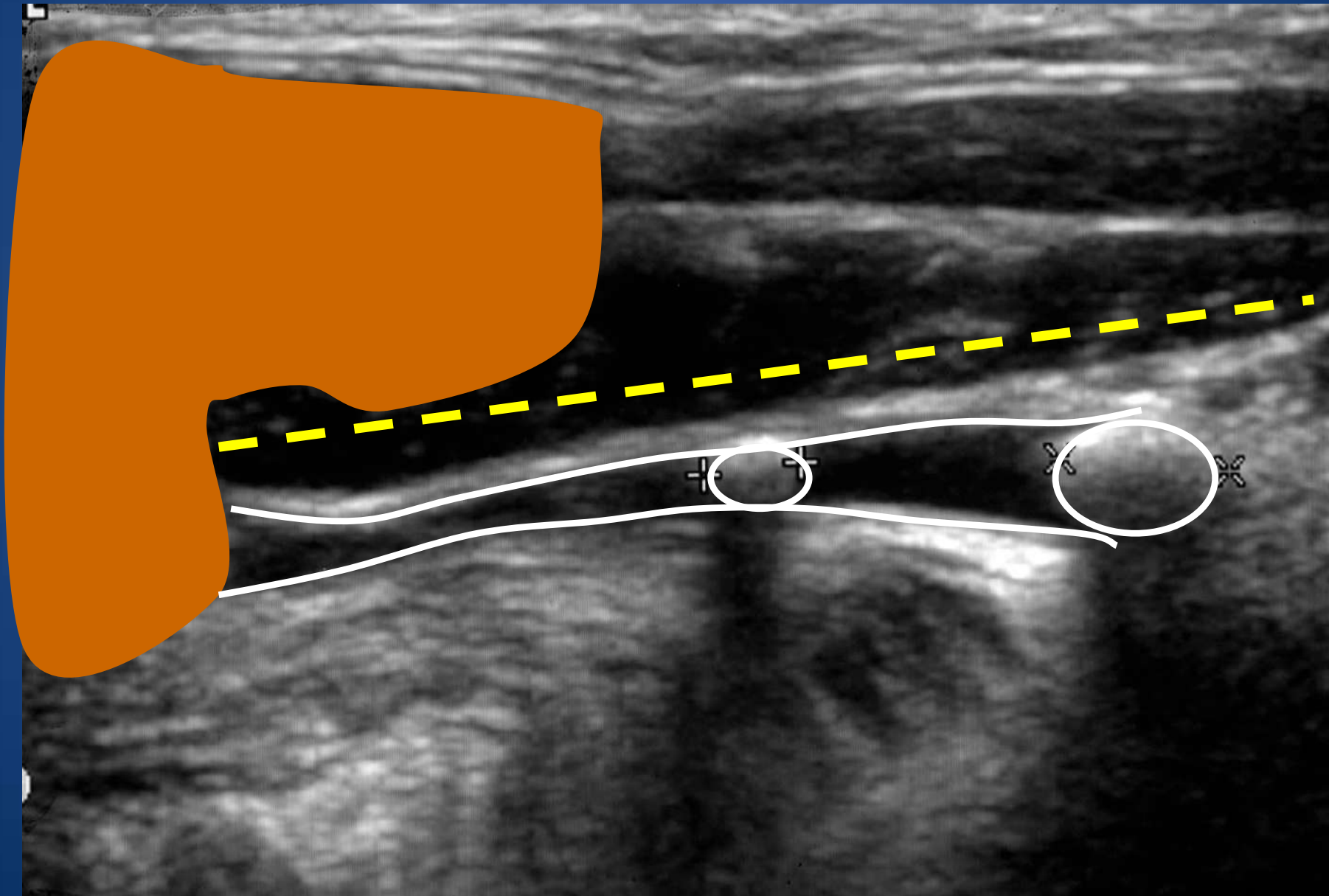
# Pitfall multiple calculi sagittal



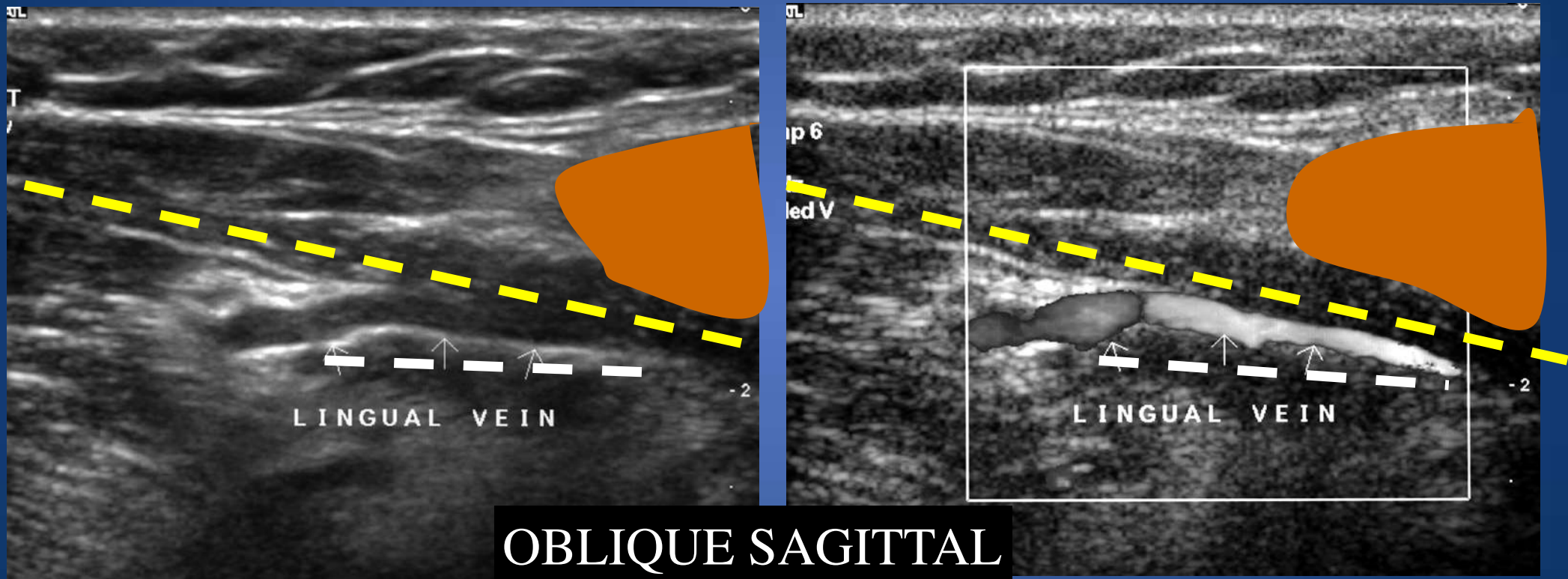
Sagittal US image showing a dilated SM duct (red arrows) secondary to obstruction by a cluster of calculi (white arrows). Note the inflamed SMG (yellow arrows).

--- Mylohyoid muscle

# Pitfall: multiple calculi US sagittal oblique

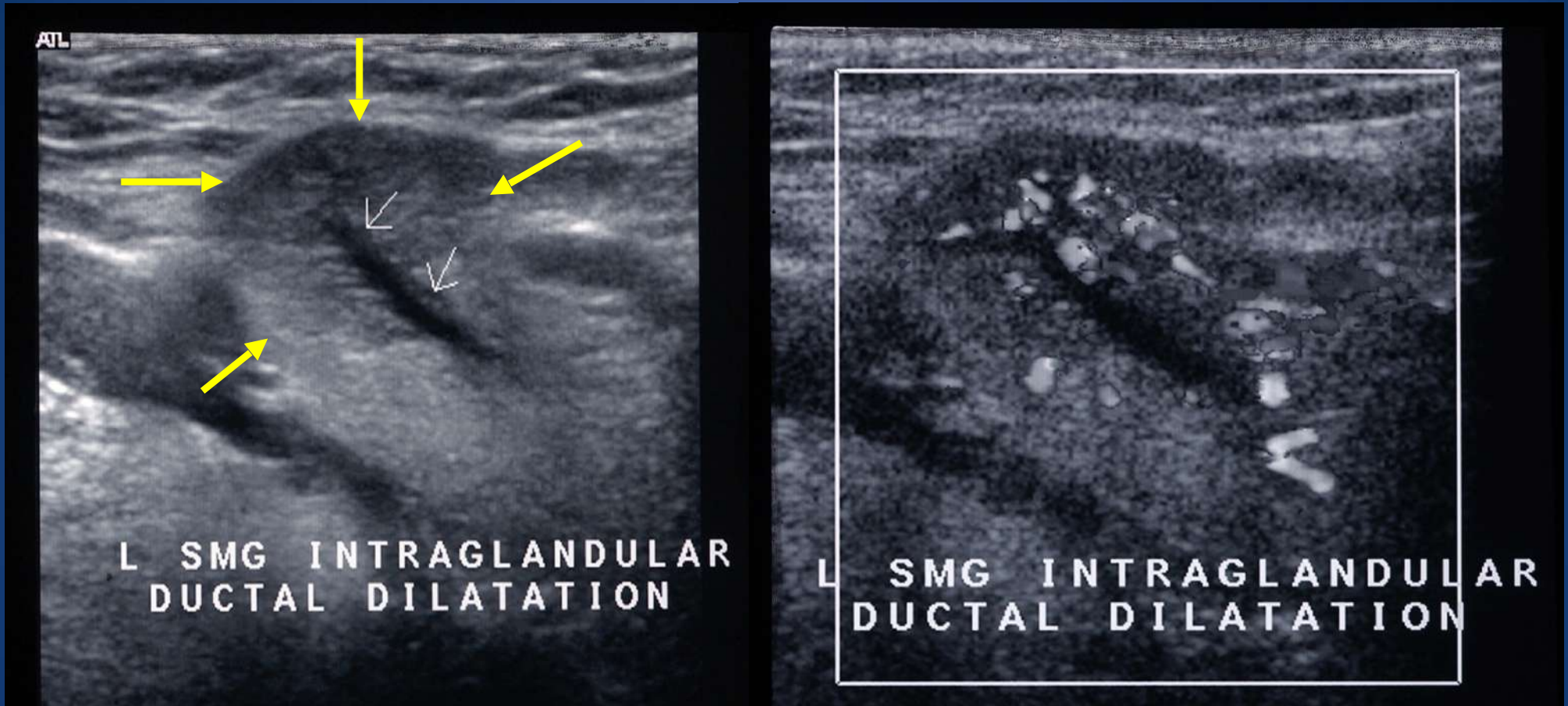


# Pitfall: Lingual Vein versus Submandibular duct



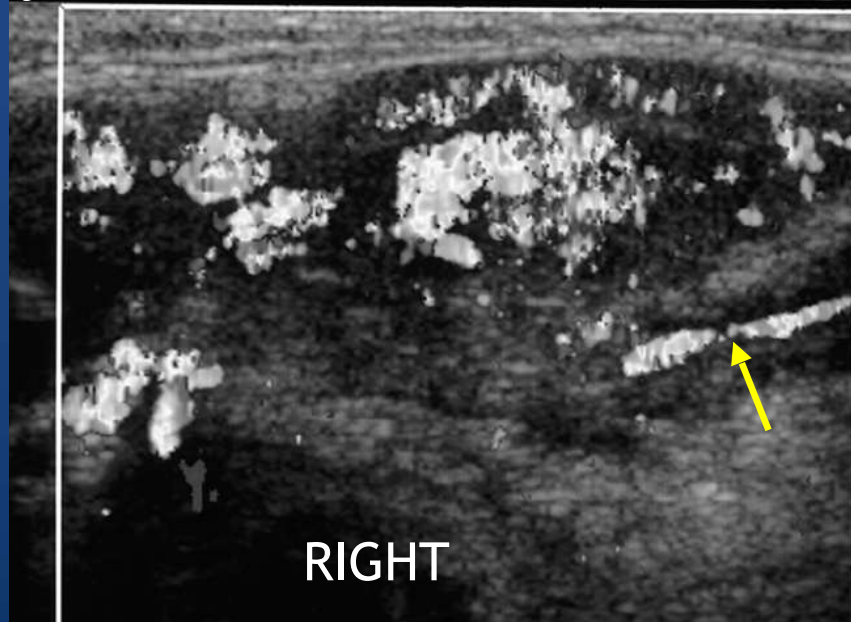
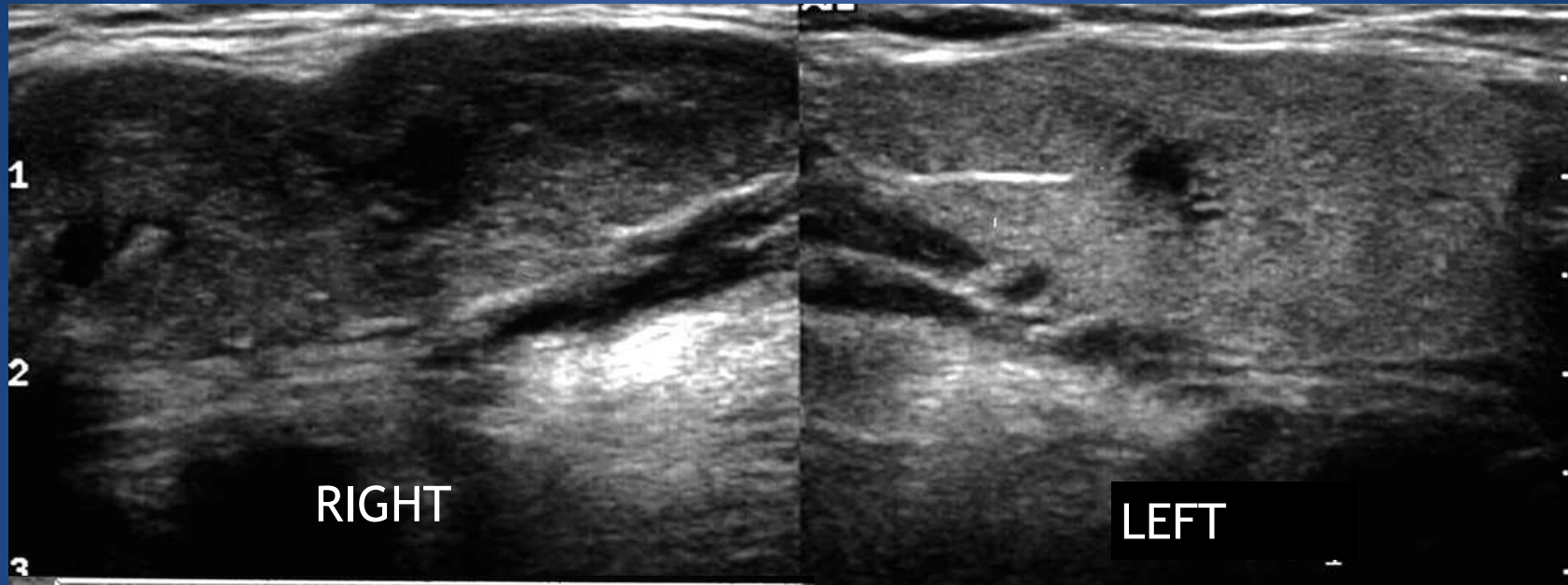
The lingual vein & submandibular duct both pass between hyoglossus & mylohyoid muscles.

# Pitfall ..Focal Sialadenitis?



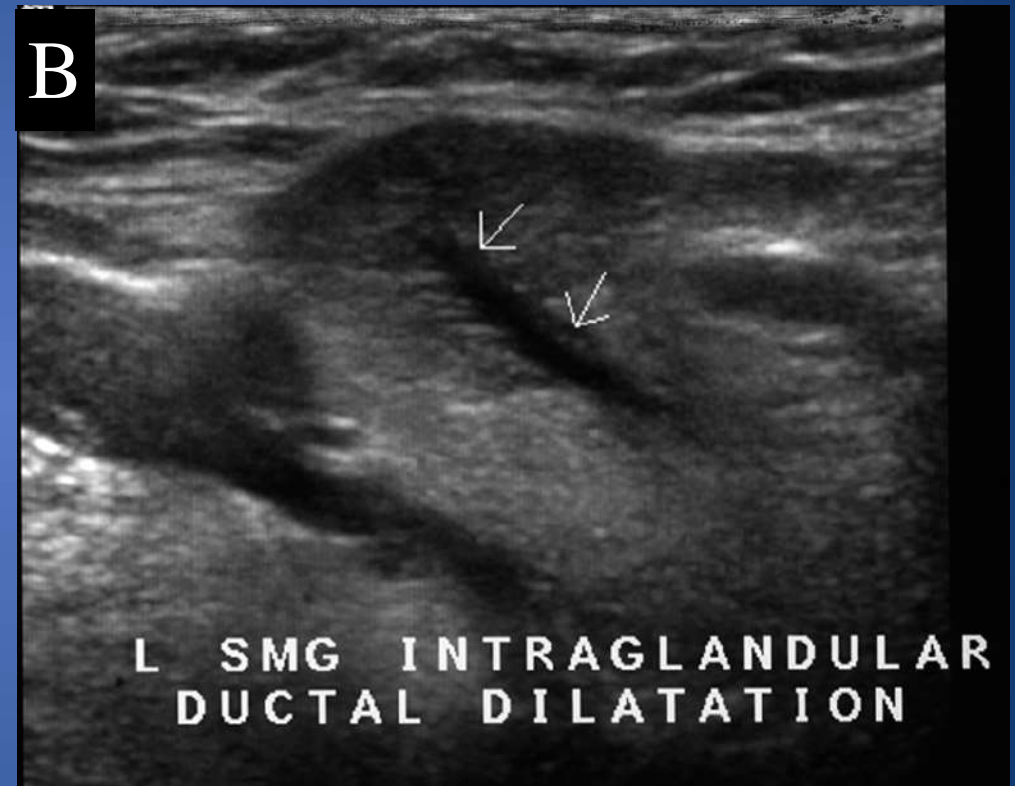
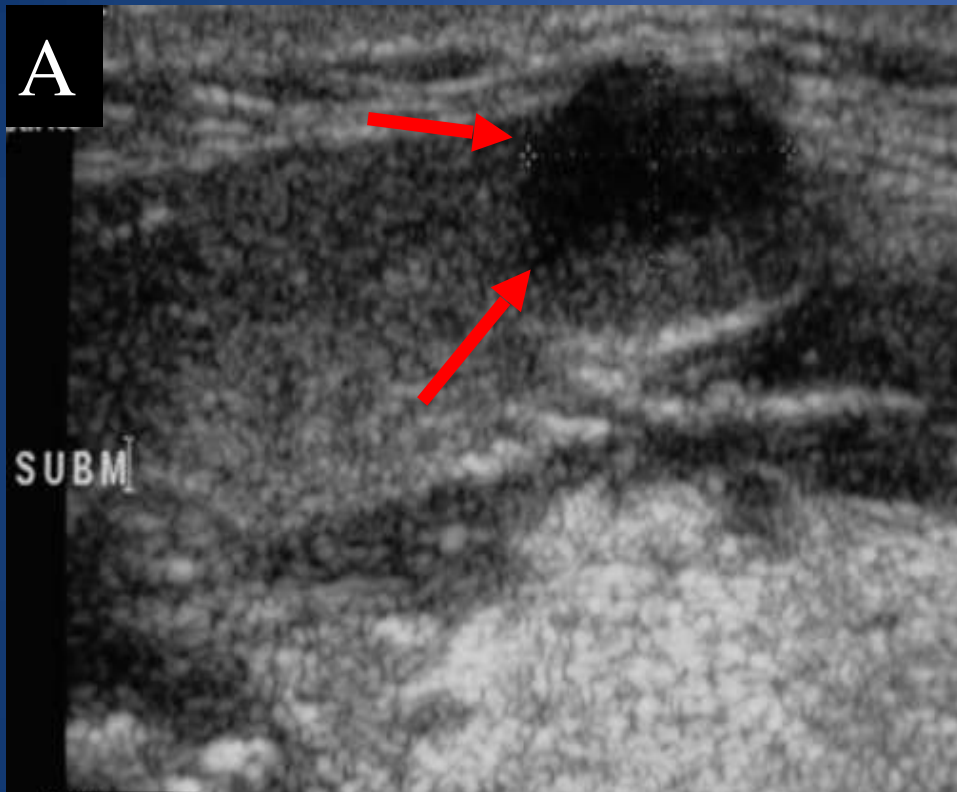
US images demonstrating a hypoechoic inflamed superficial lobe of the left SMG (yellow arrows) with dilatation of the intraglandular duct (white arrows) & increased Doppler flow.

# Submandibular Sialadenitis



Oblique sagittal US images showing a uniformly hypoechoic inflamed right SMG (with increased vascularity on colour Doppler) & normal echogenicity of the left gland. Arrow indicates the lingual vein between the mylohyoid & hyoglossus muscles.

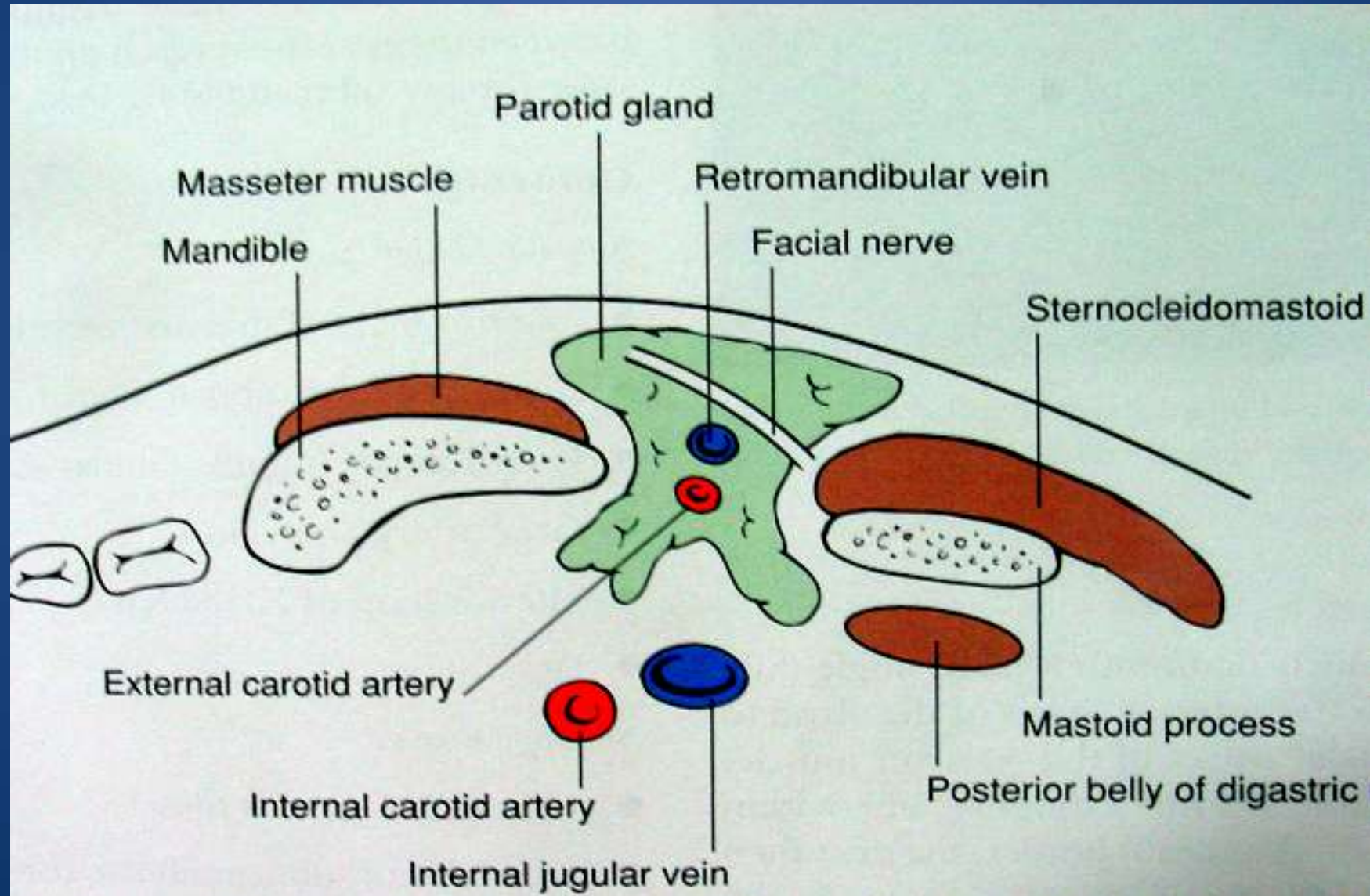
# Pitfalls: Sialadenitis versus Tumour



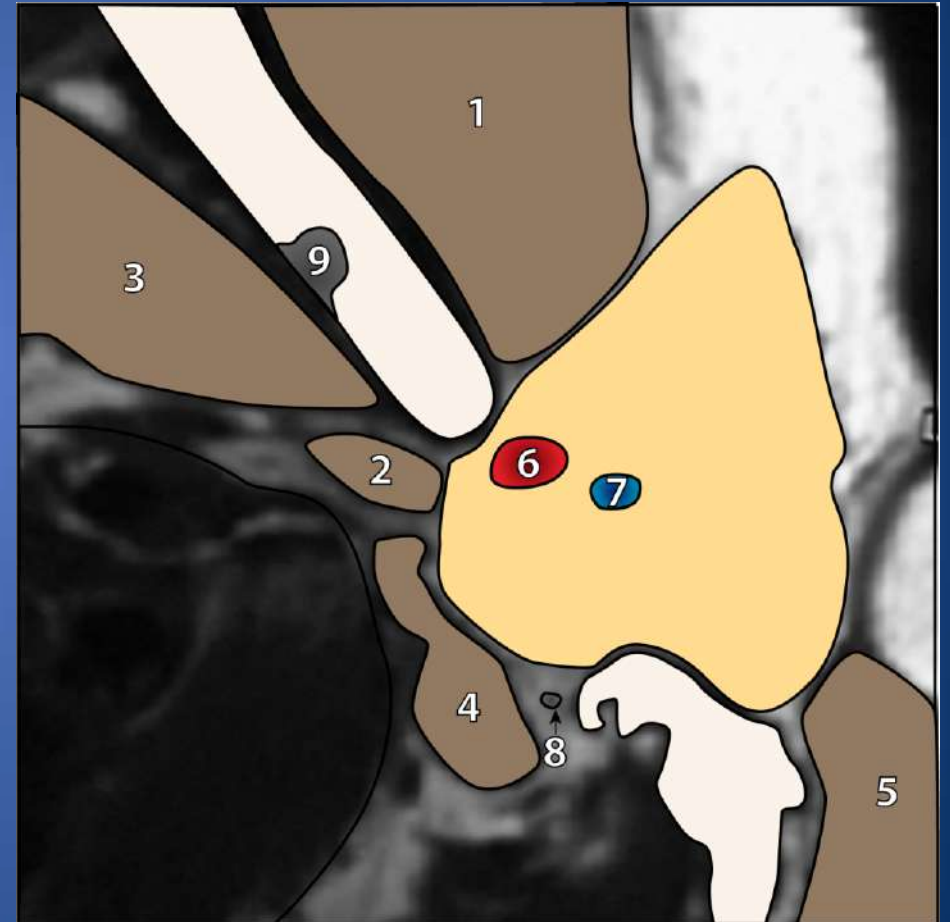
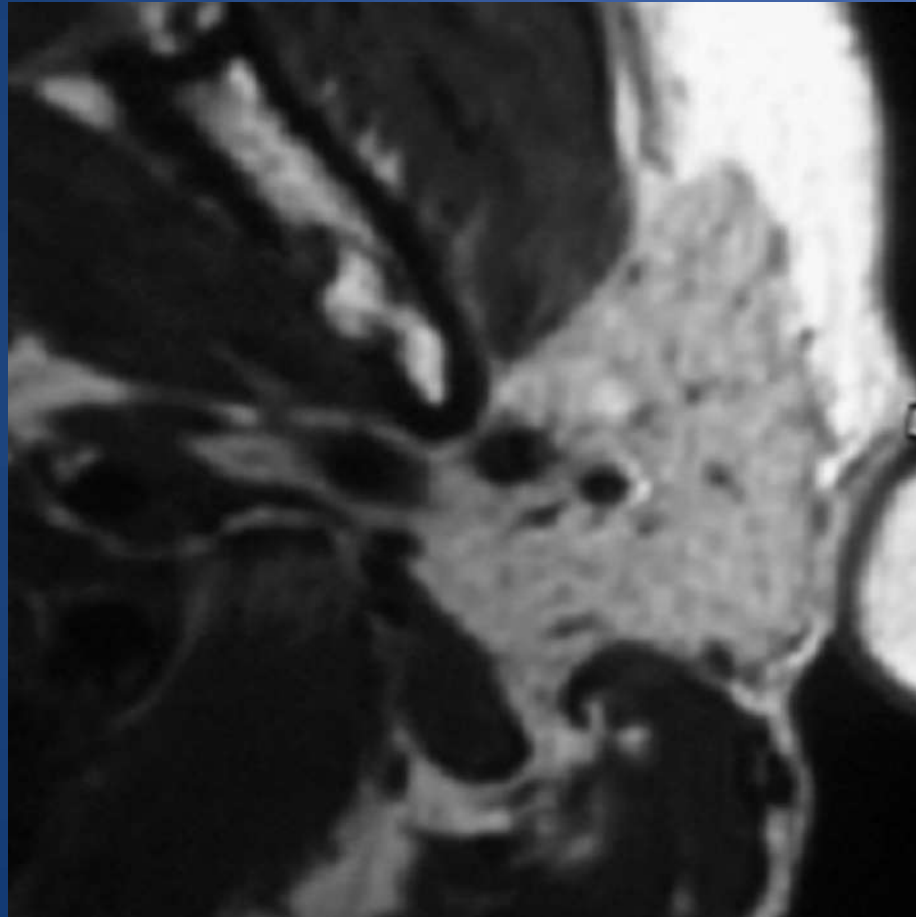
# Parotid Sialolithiasis

- 20% of calculi occur in the parotid duct.
- < 50% of stones are radioopaque on plain film.

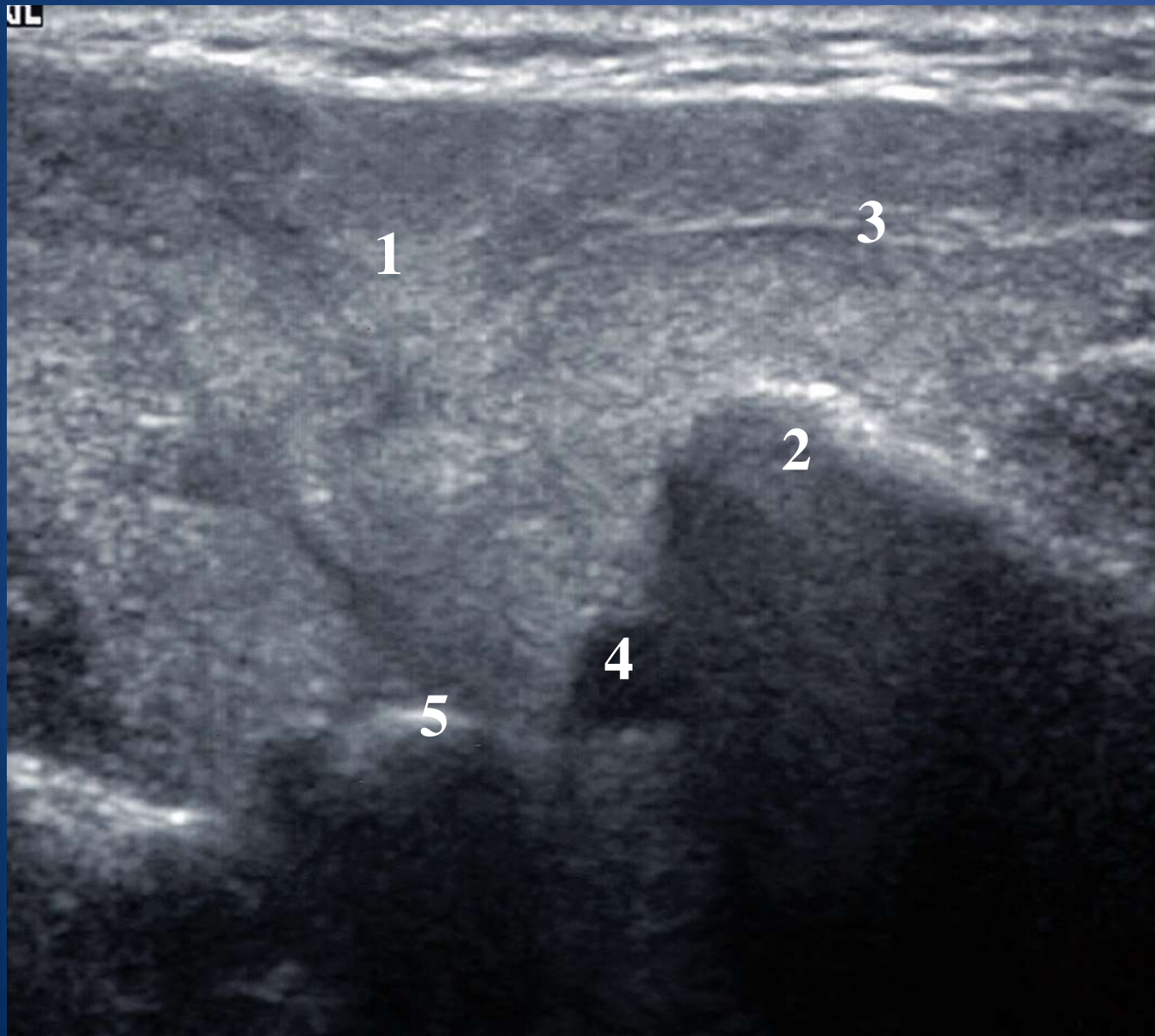
# Normal Anatomy Of the Parotid Region



# Parotid Anatomy



# Ultrasound Anatomy: Parotid Gland



Axial US image of a normal parotid gland (1).

2= Mandible

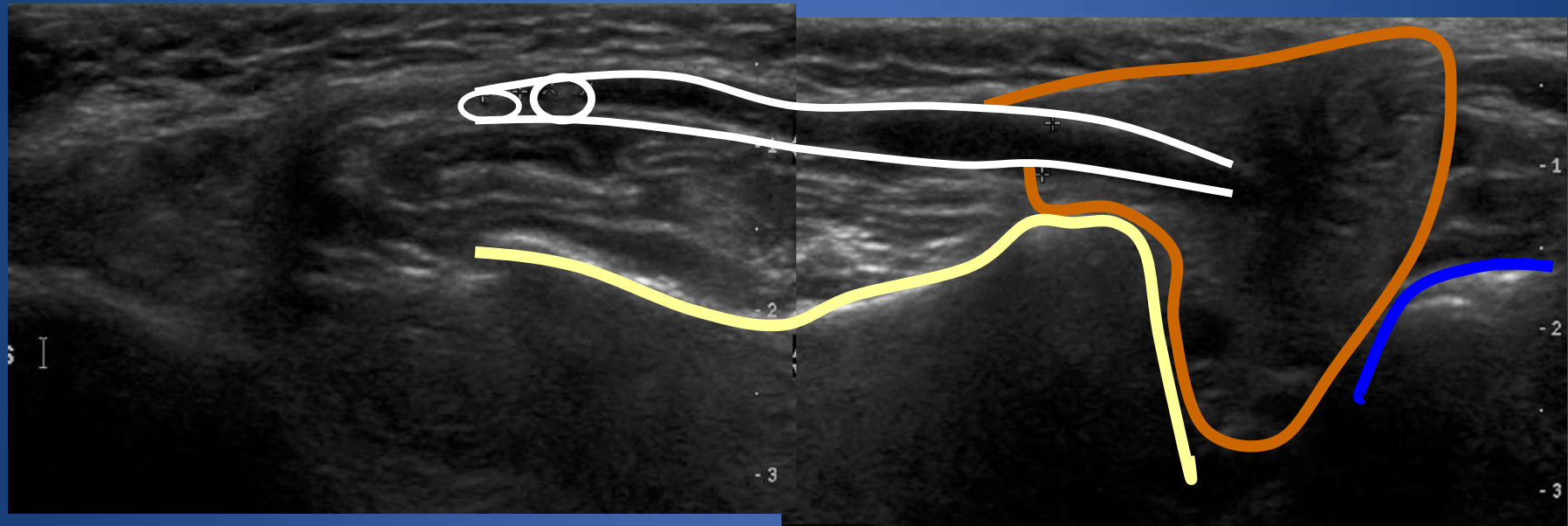
3= Parotid duct

4= External carotid artery

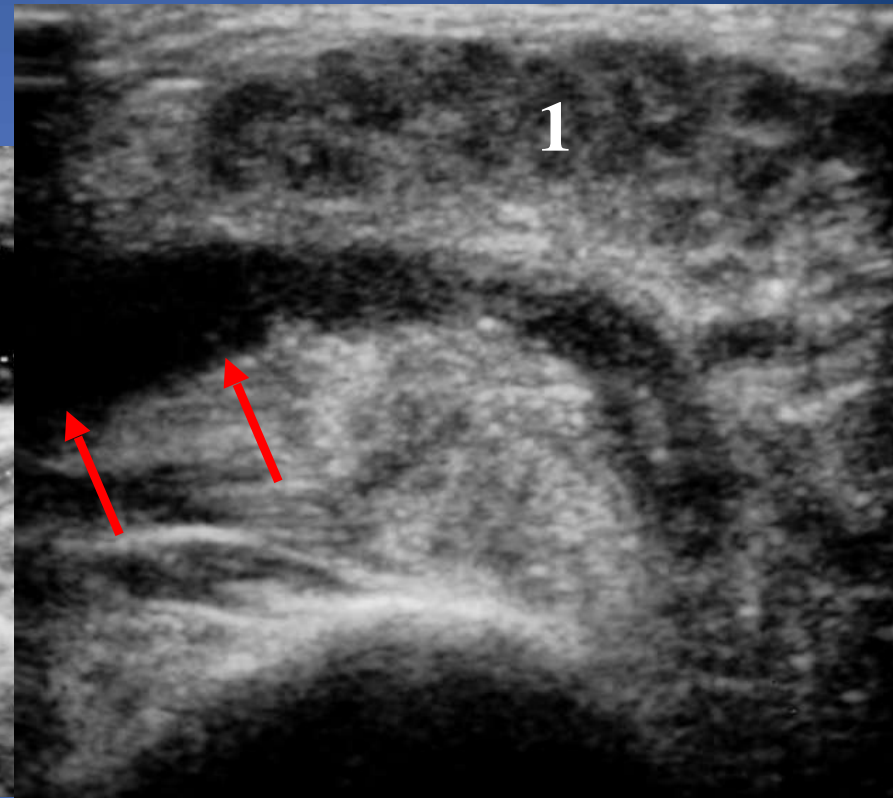
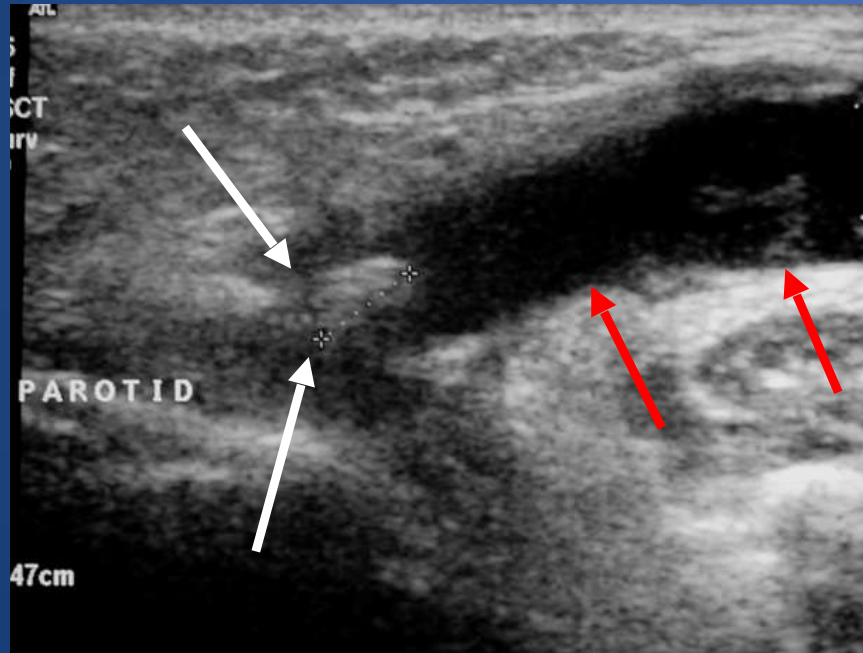
5= Styloid process



# Parotid obstruction



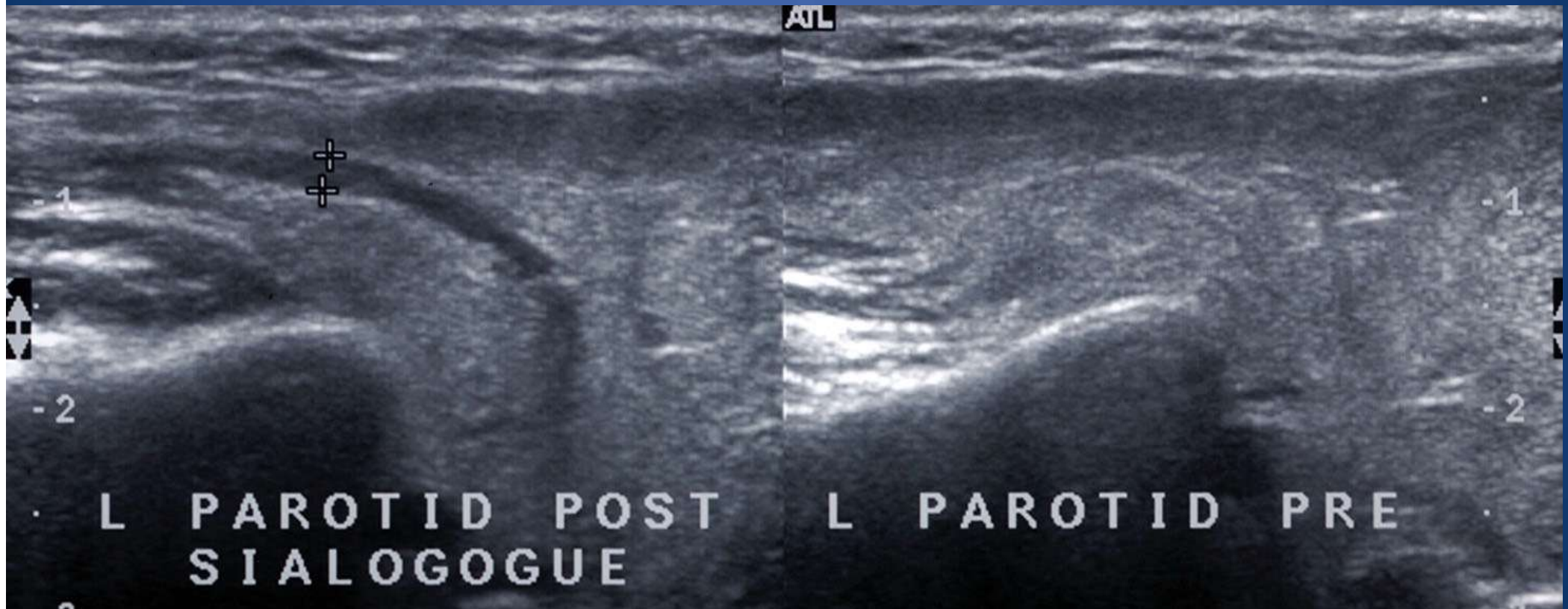
# Obstructive Parotid Sialadenitis Secondary to Calculus



Note thick wall of chronically inflamed duct

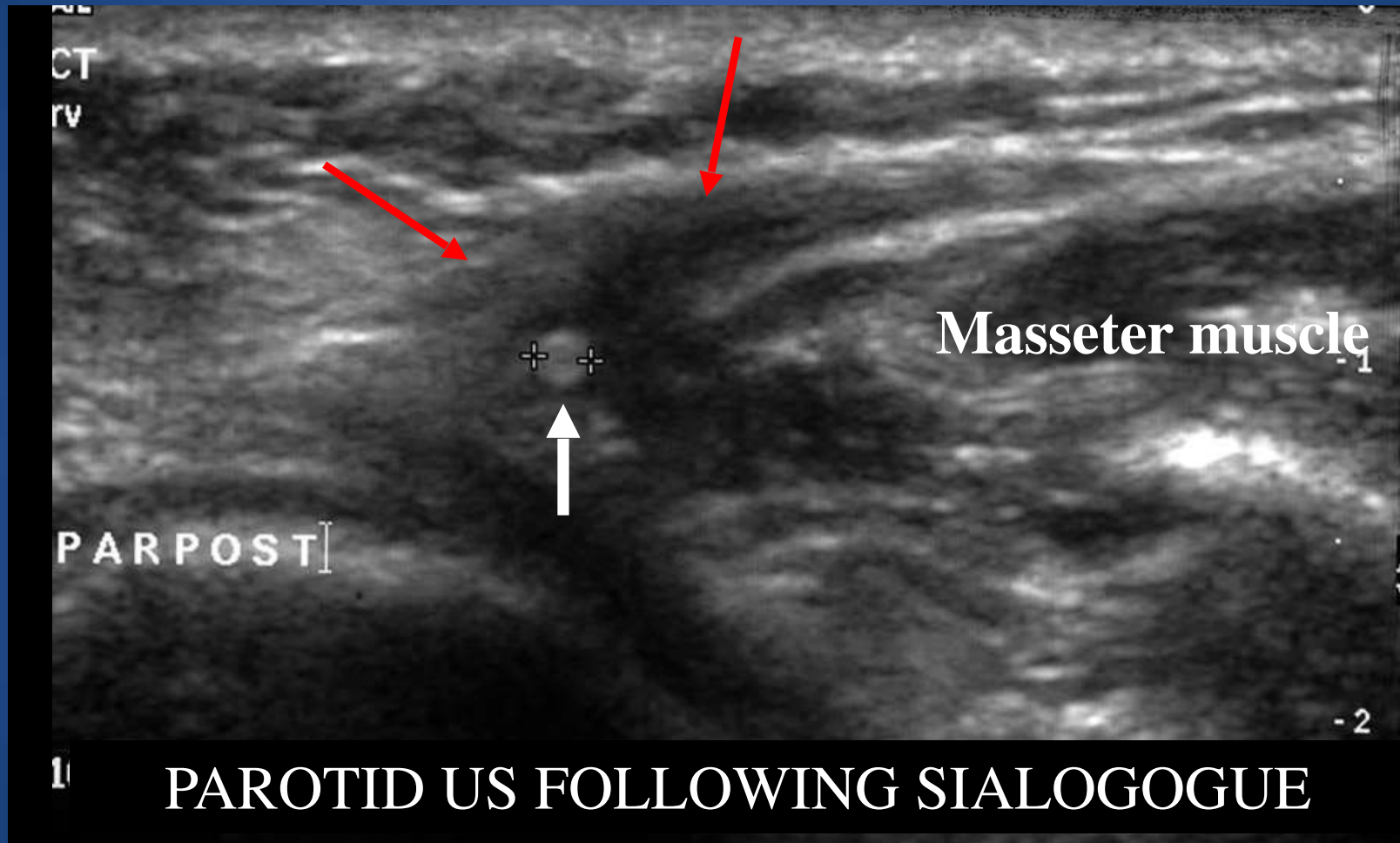
# Tip: use sialogogue

## Parotid Gland



Post & pre sialogogue images of the parotid demonstrates the ductal anatomy.

# Useful Tip: US the Parotid Duct Orifice



→ 0.16cm calculus at the ductal orifice

→ Buccal fat pad

# Summary: salivary colic

- History and examination important
- US Technique
  - +/- sialogogue
  - probe angle impt and gentle pressure
  - Examine all 6 major salivary glands ..always
- Do not forget obstructing tumour
- Do not forget multiple calculi
- Do not forget bilateral calculi

Two main groups of patients with presenting symptoms of:

- Obstructive or chronic inflammatory/ autoimmune salivary symptoms (salivary colic)
- or a mass..... ? Salivary in origin

Some overlap between groups

Background:  
Tumours of the **Parotid**:

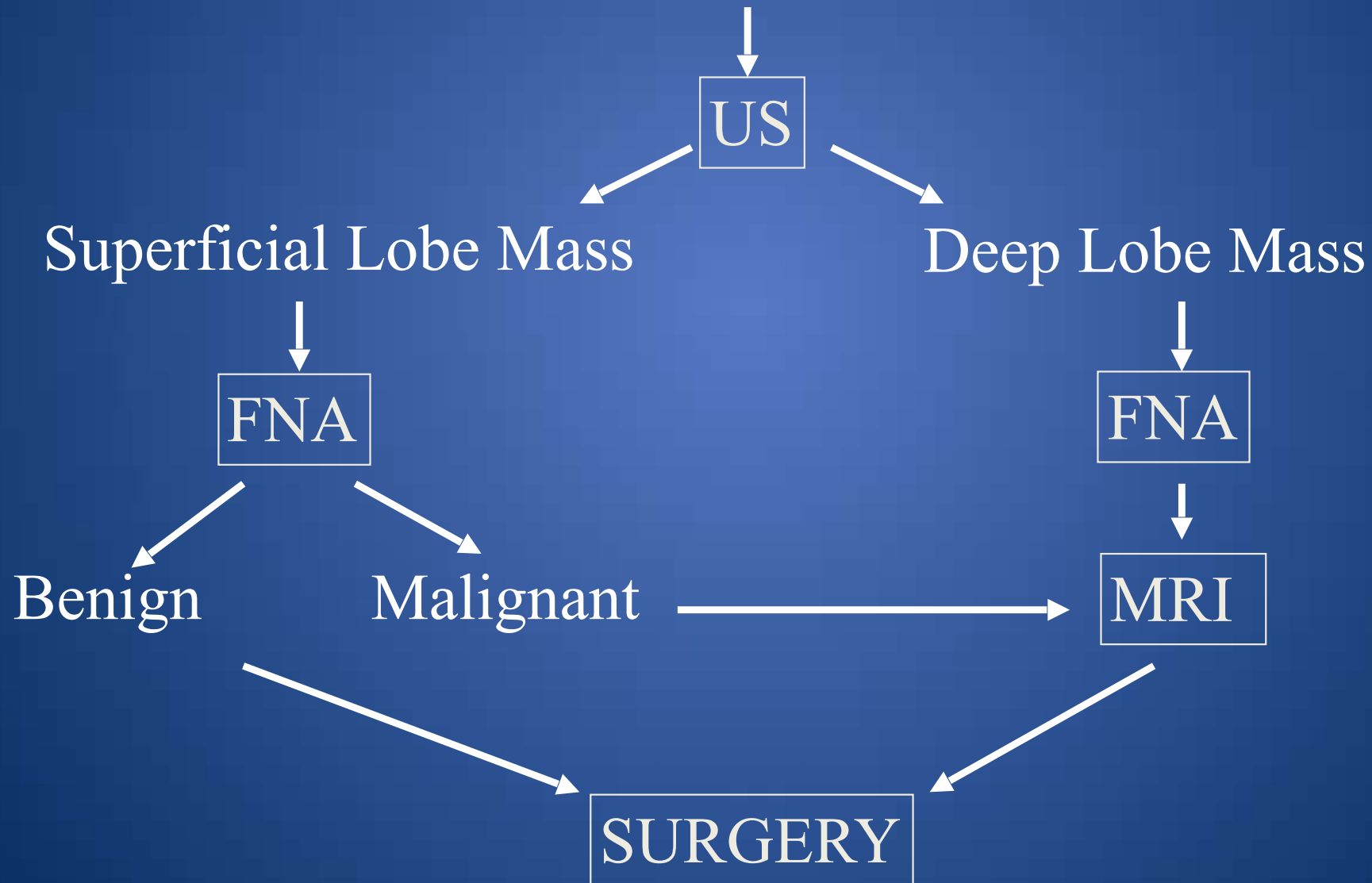
- **80%** of all salivary neoplasms
- **80%** benign
- **80%** superficial lobe (usually in the tail).
- **80%** pleomorphic adenoma
  
- (5-10%) Warthin's tumour (bilateral in 10-20%)
  
- Mucoepidermoid the most common malignancy

Parotid US:  
Localization of Lesion  
Questions to answer

- Intra- or extraparotid?
- Superficial versus deep?
- Single or multiple
- Unilateral or bilateral
- Cystic or solid
- Ill- defined or well defined
  
- ? + nodes

# Imaging Algorithm: Parotid Mass

## PAROTID MASS



# Pitfalls in salivary imaging

Deep lobe extent (parotid)

Atypical Facial N palsy (parotid)

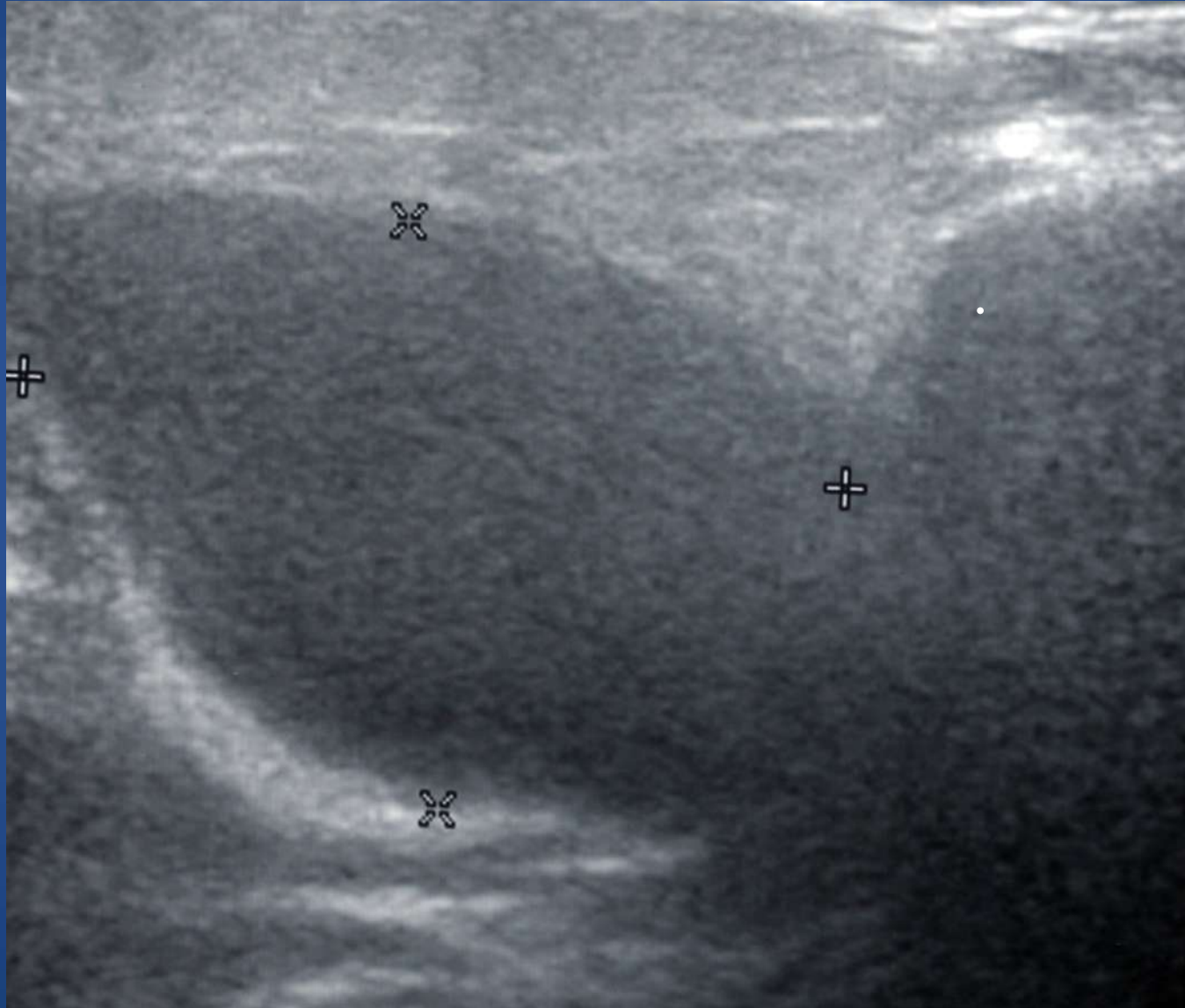
Cystic salivary lesions

Inflammation v tumour

Sublingual/minor salivary tumours

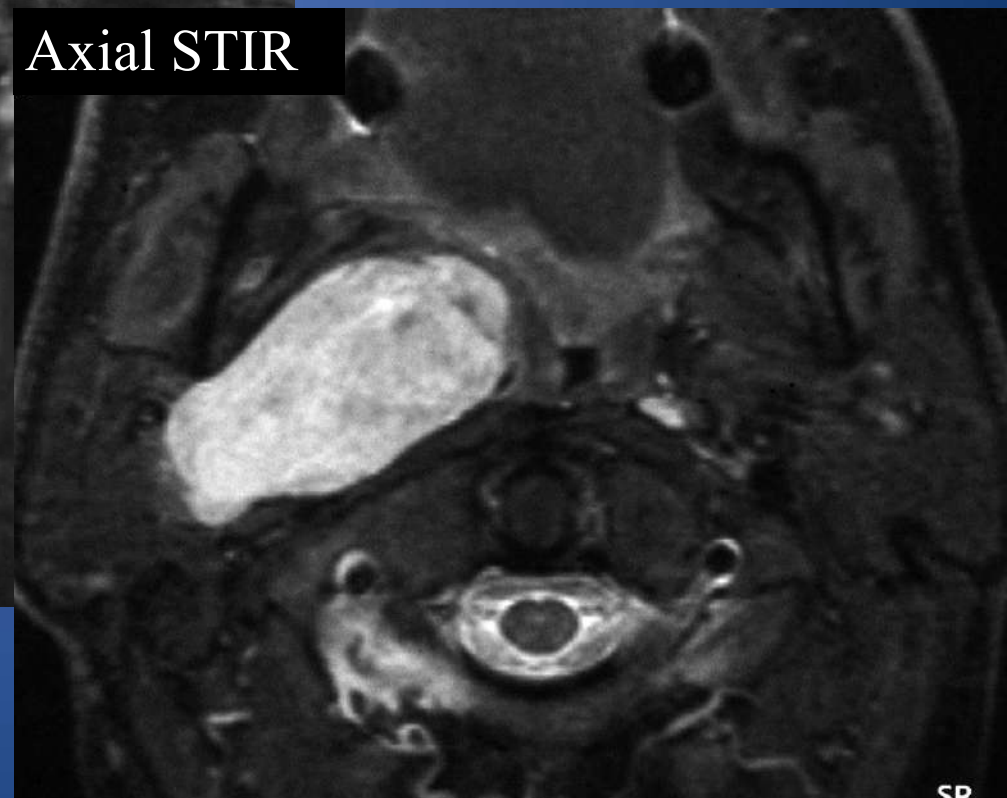
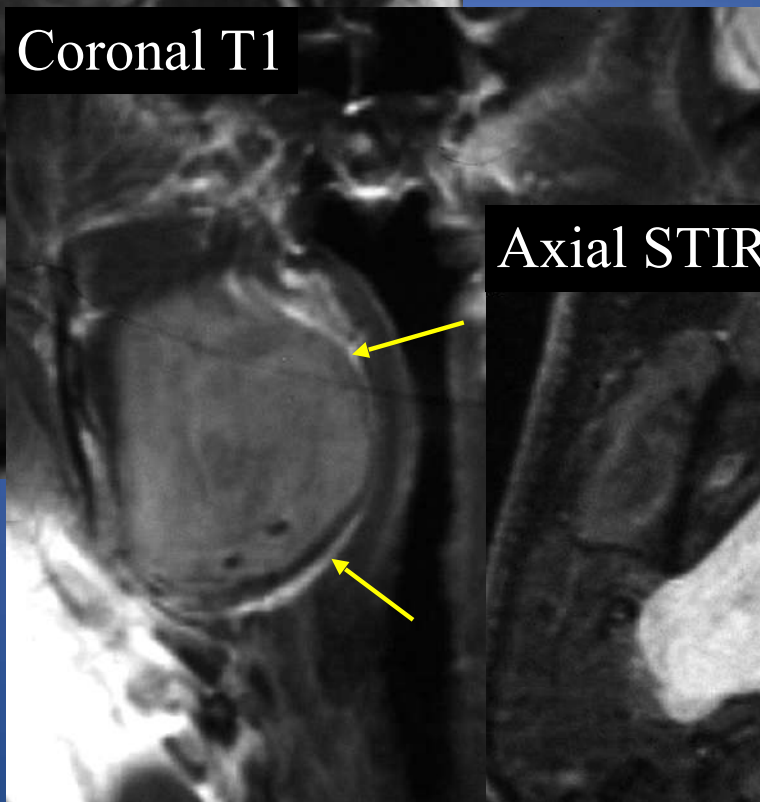
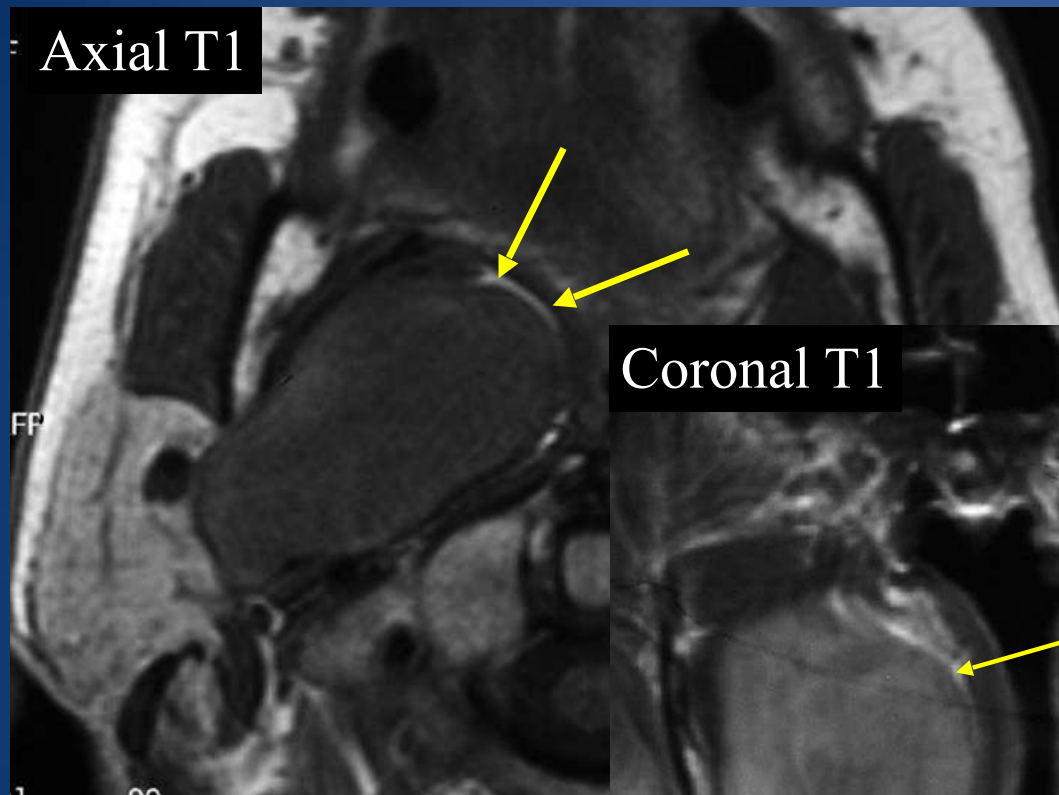
Lymphoma in Sjogrens

# Deep Lobe of Parotid Tumour Tip of the iceberg!



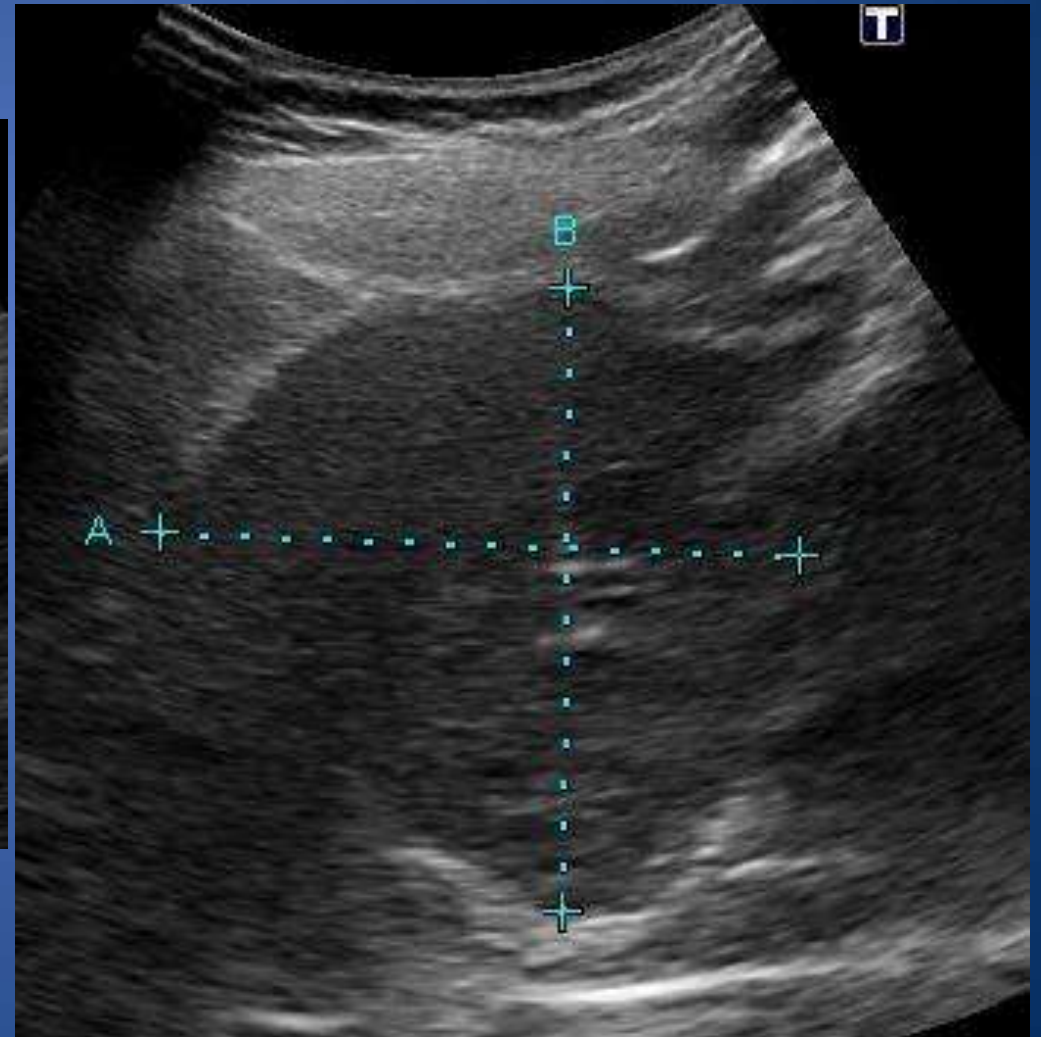
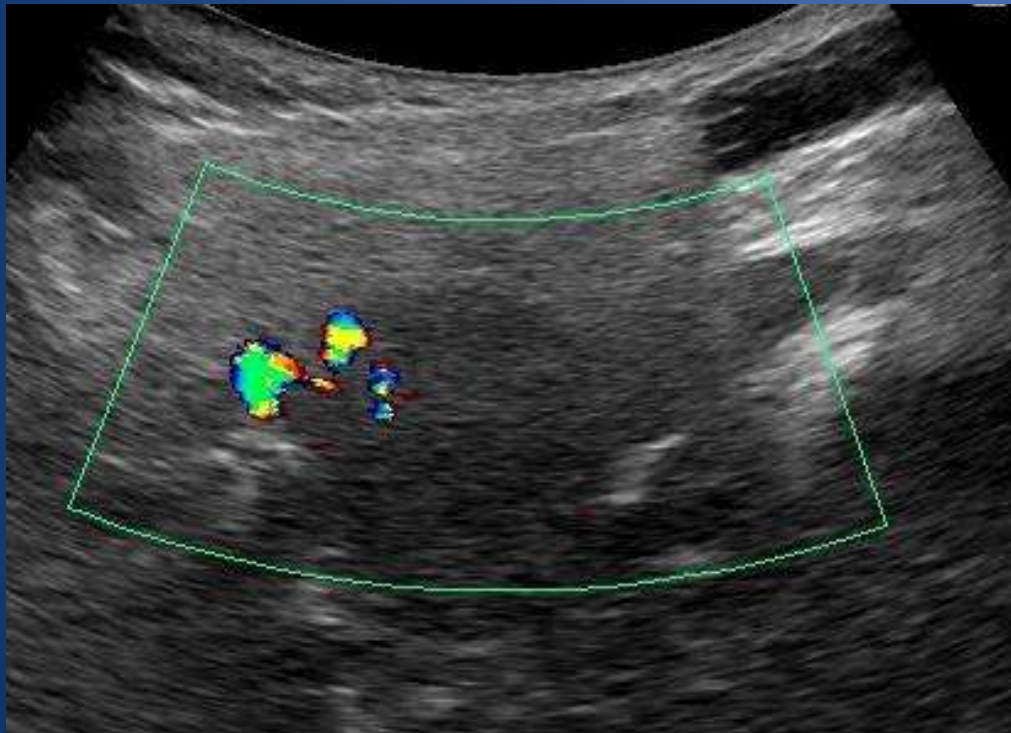Tip : Use a curvilinear probe

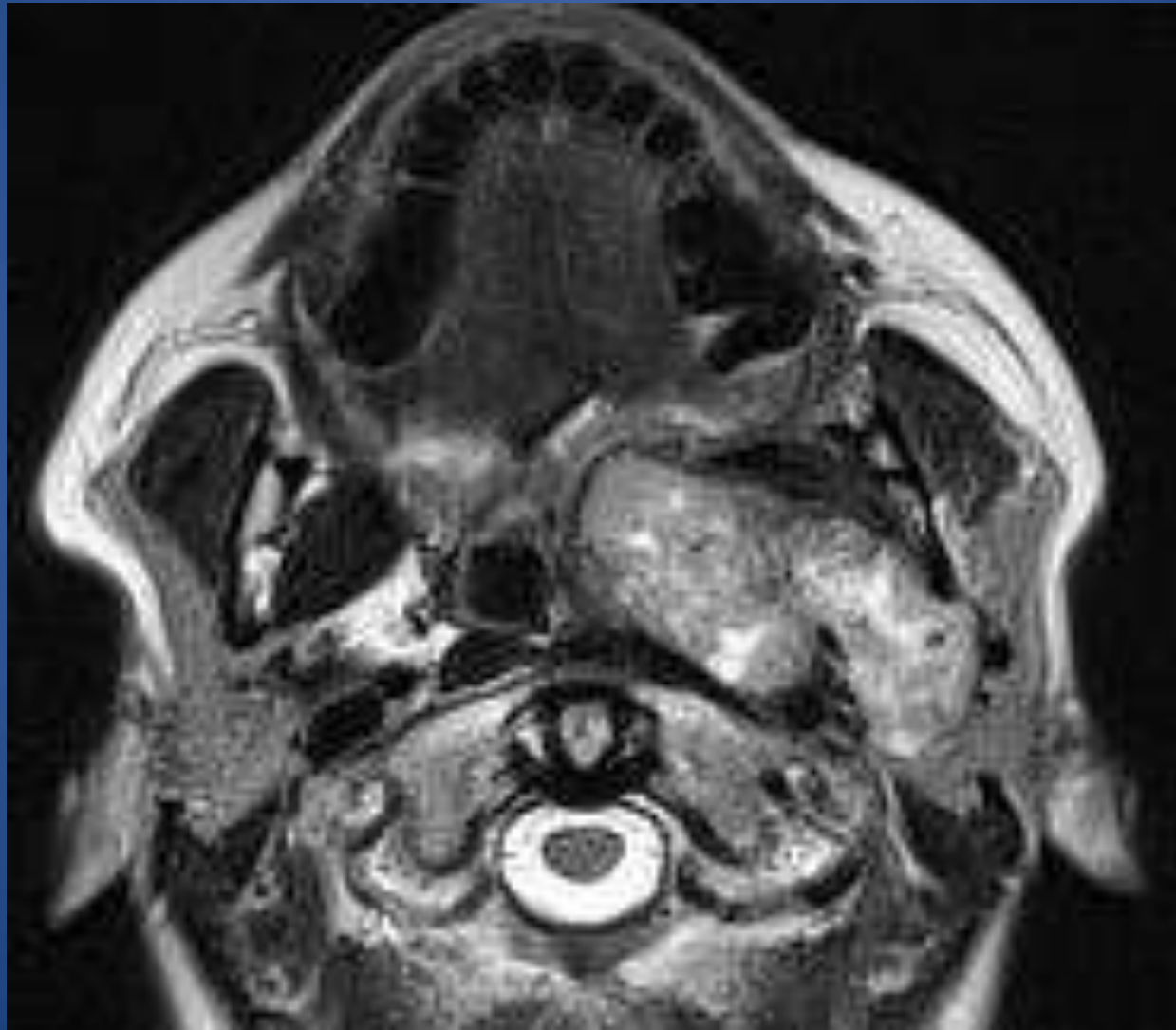
# Deep lobe of Parotid Tumour



→ = Fat signal in PPS

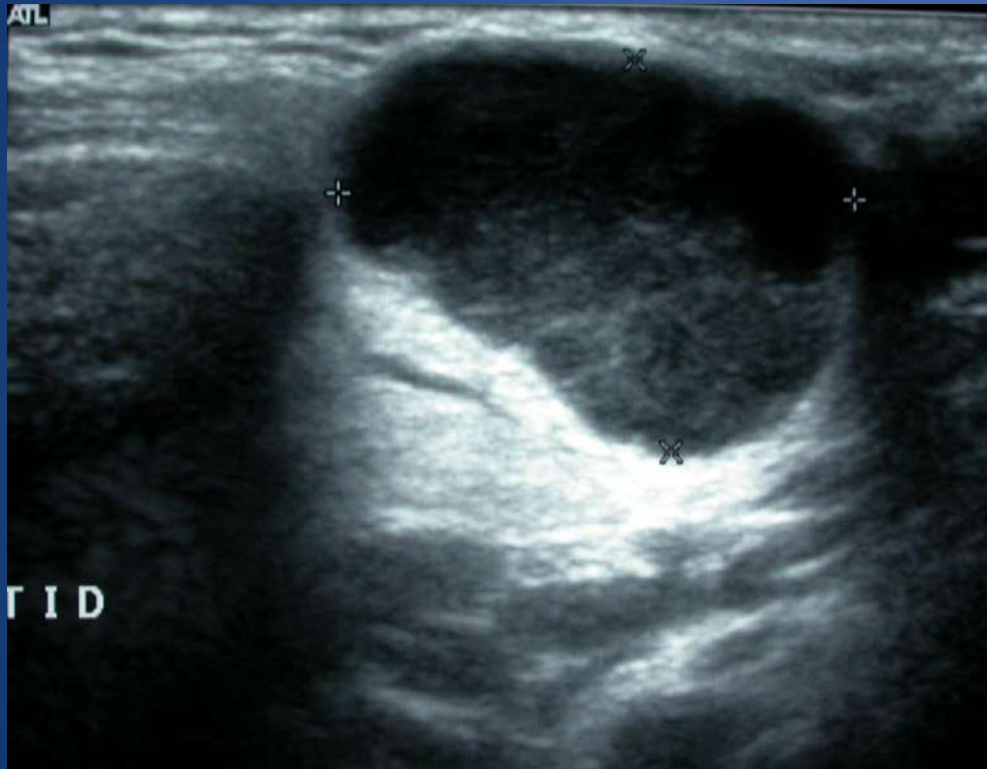# Curvilinear probe and spinal needle for FNA



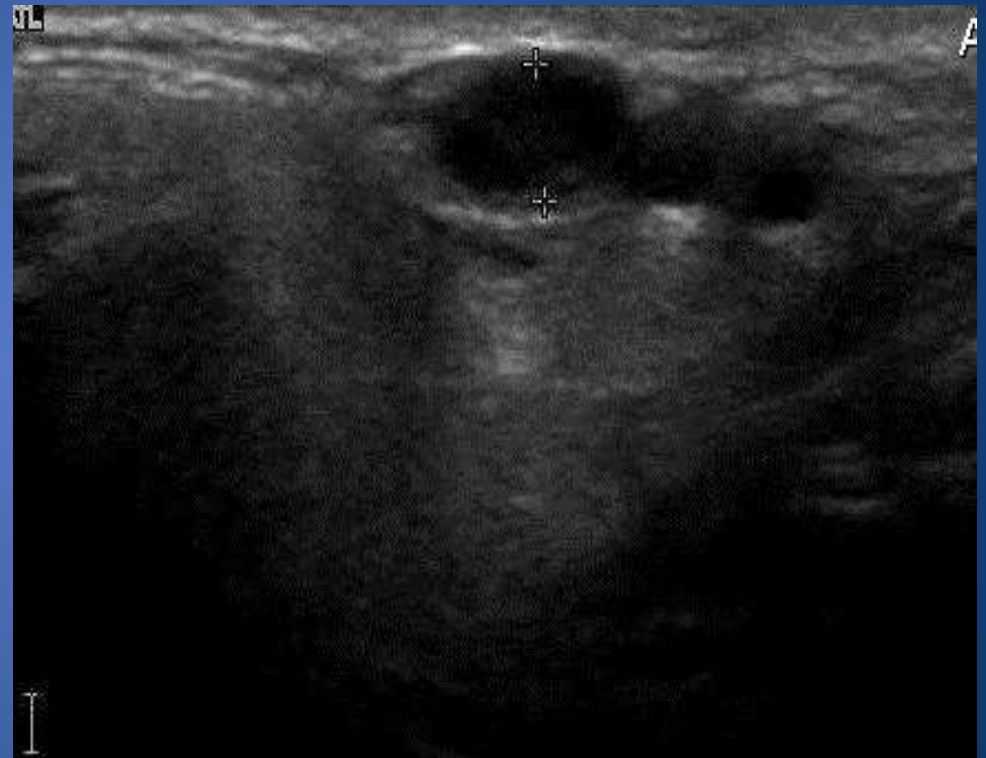

# Common Tumours

## Pleomorphic Adenoma

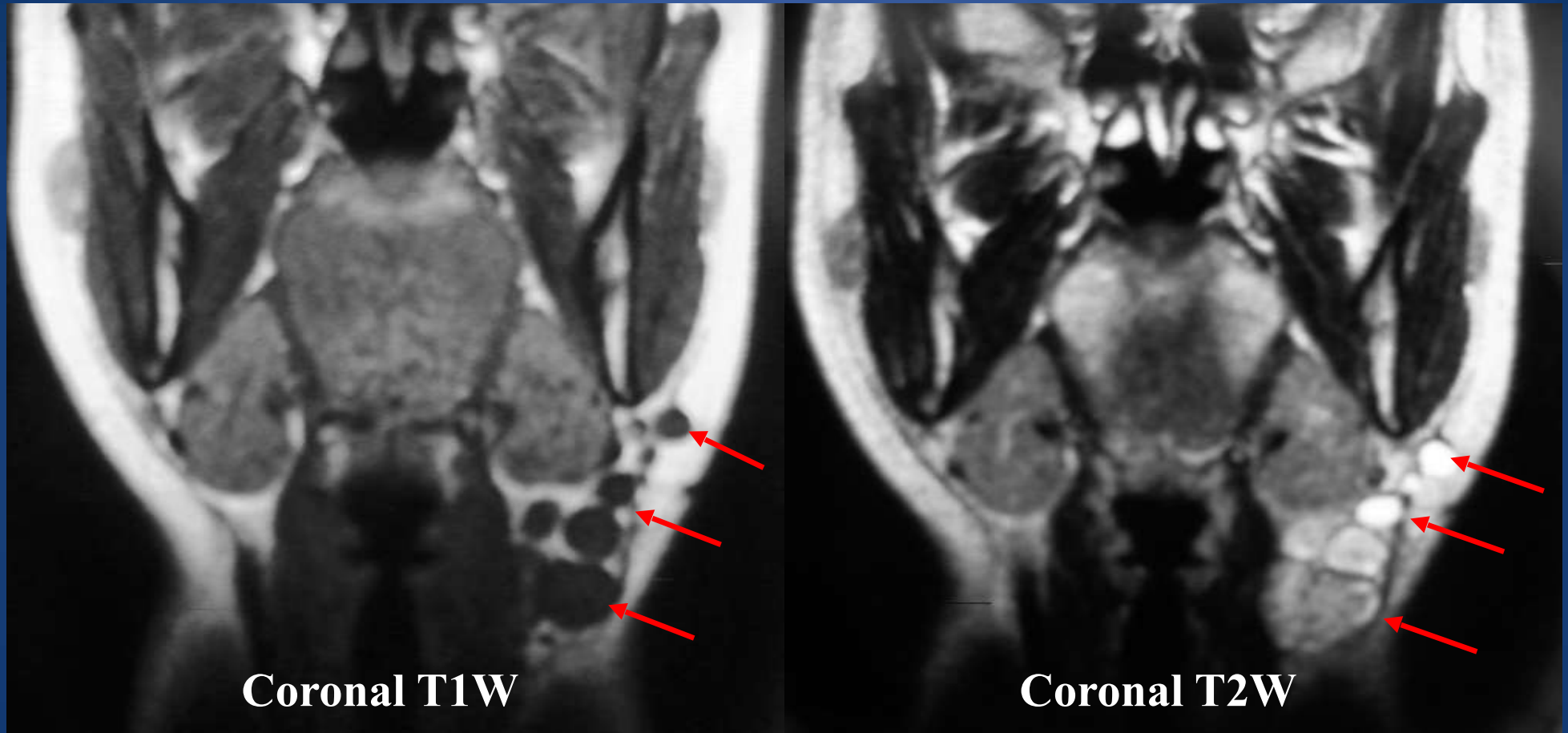


Note the hypoechoic lobulated outline & posterior acoustic enhancement.



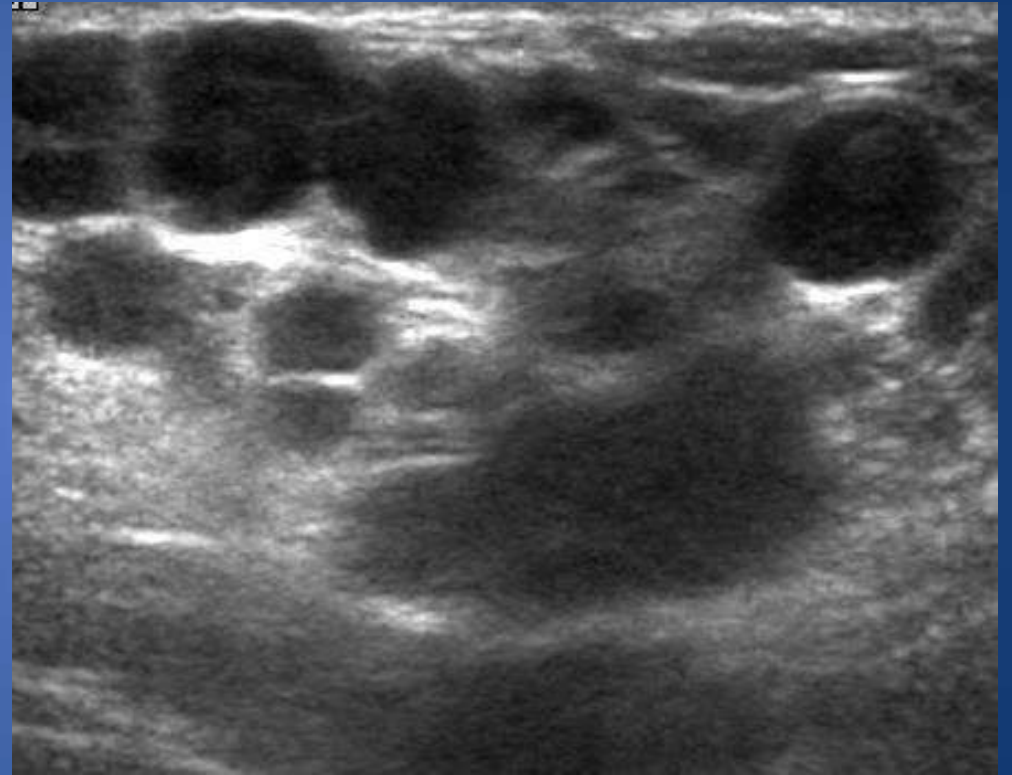
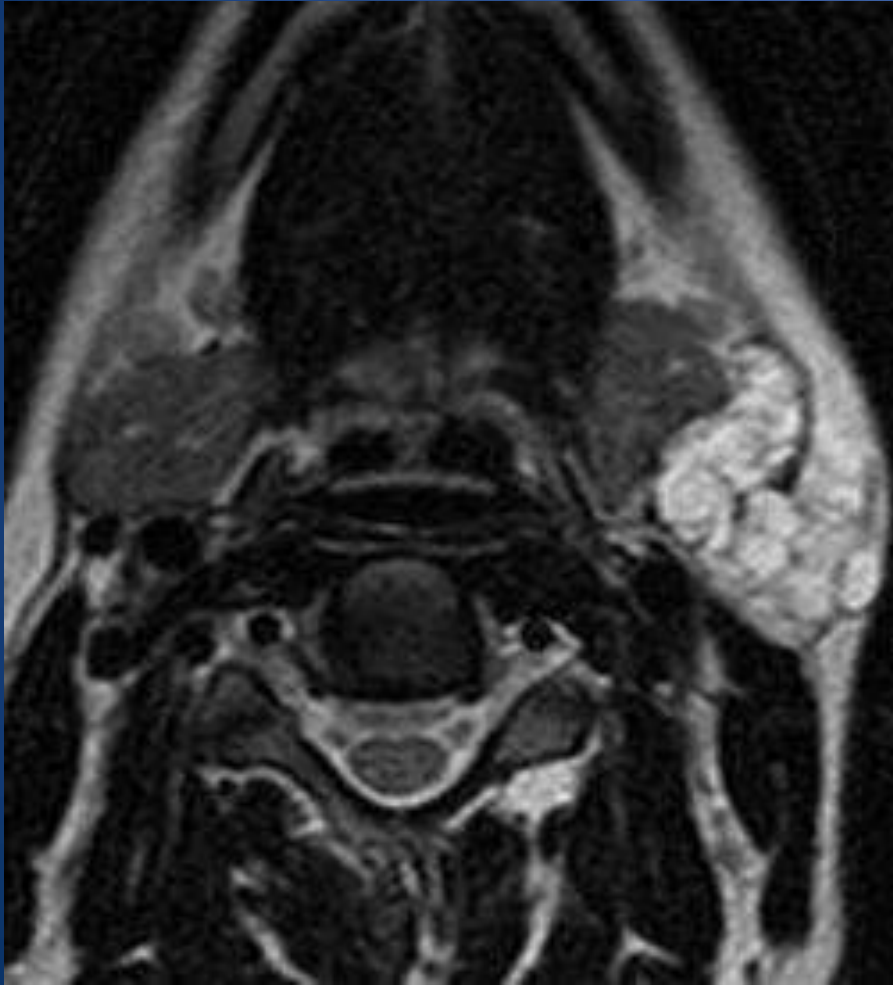
Recurrent pleomorphic

# Recurrent Pleomorphic Adenoma



Coronal MRI images demonstrating multiple foci of recurrent pleomorphic adenoma in the left submandibular region (arrows).

# Recurrent PSA



# MRI salivary tumours

## Benign features:

- Low signal rim
- Round/lobulated mass
- High signal on T2

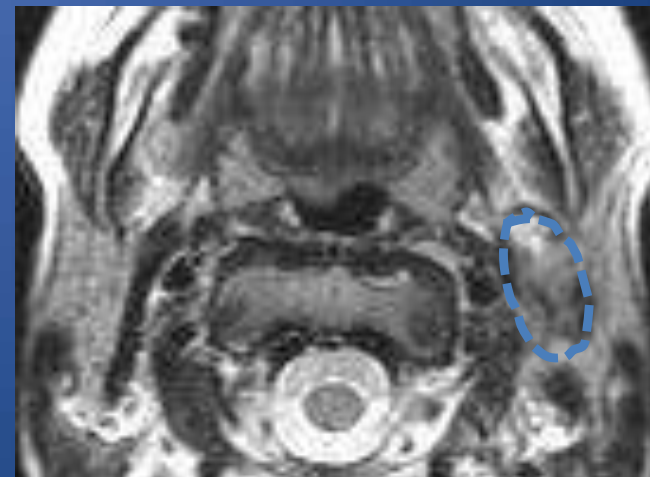
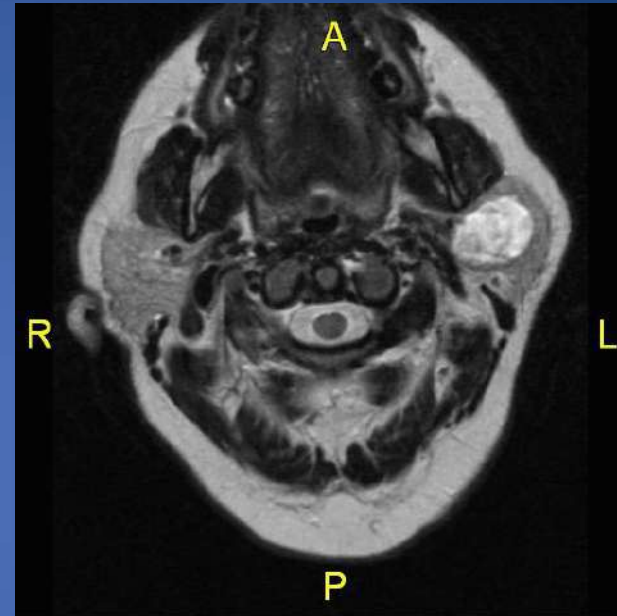
## Malignant features:

Irreg tumour margins

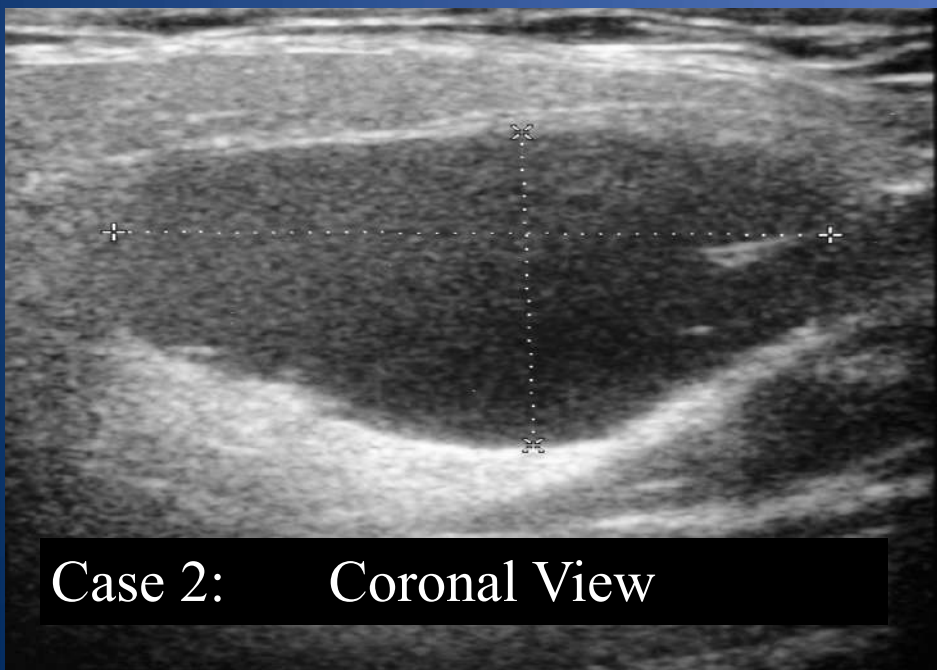
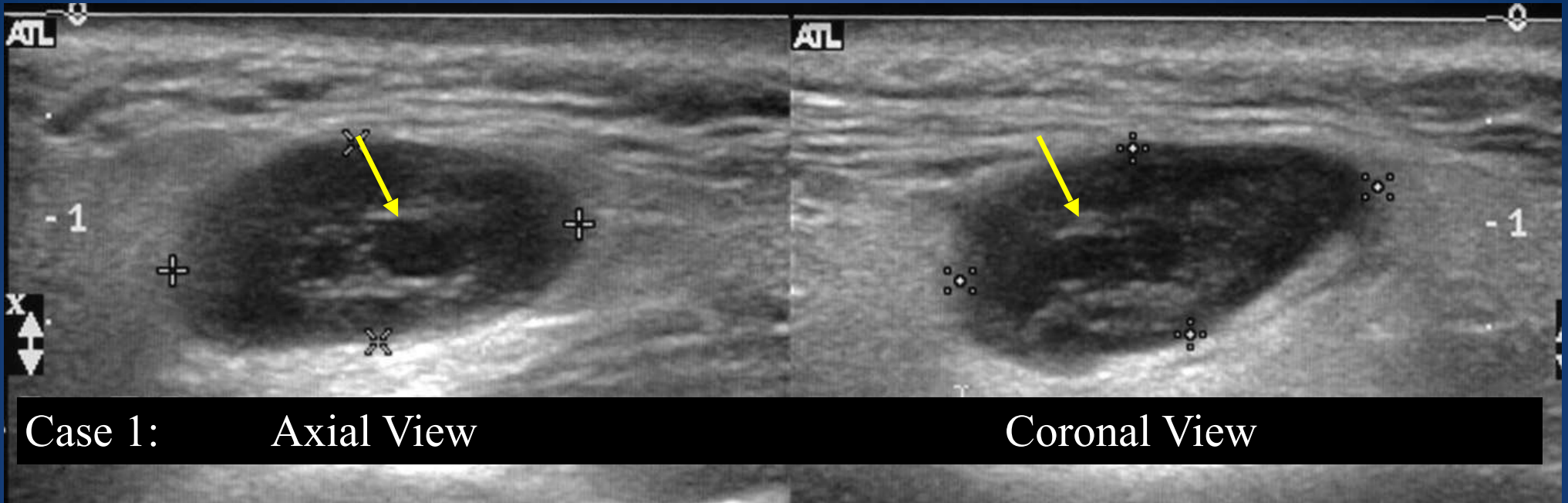
Invasion

Heterogeneous &

hypointense signal on T2

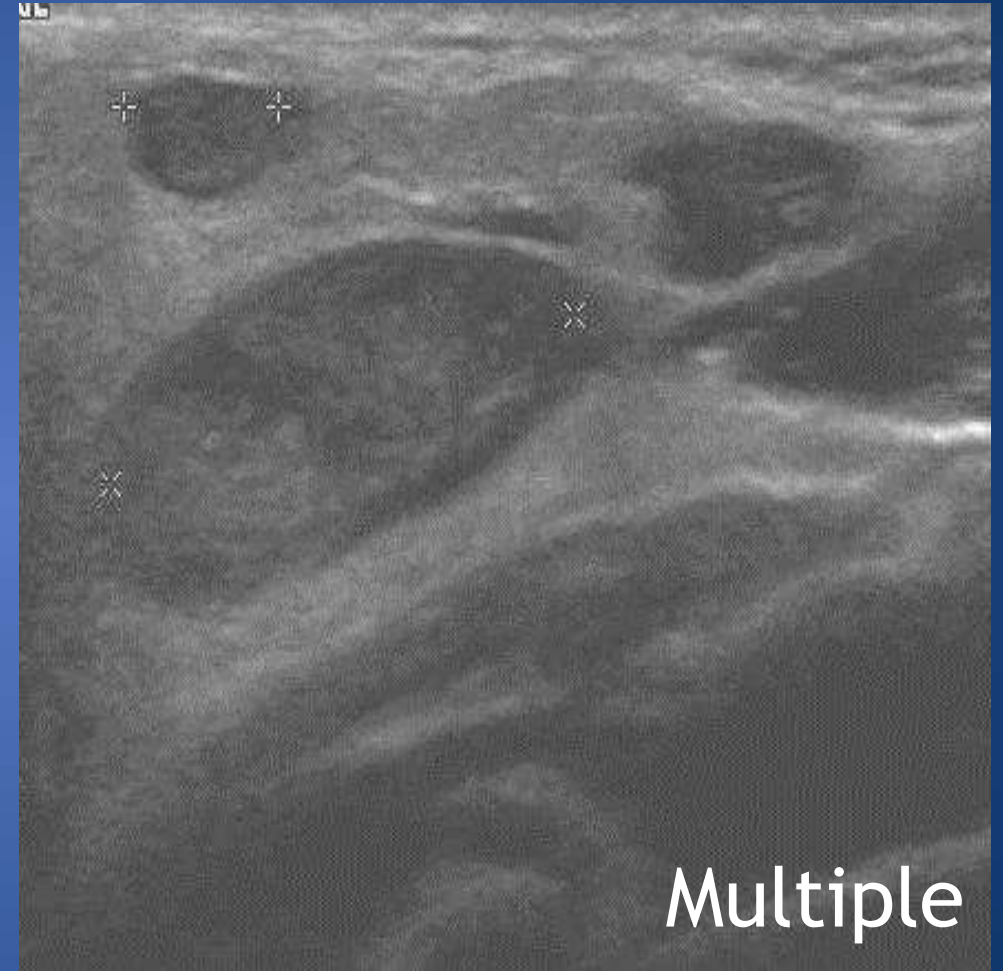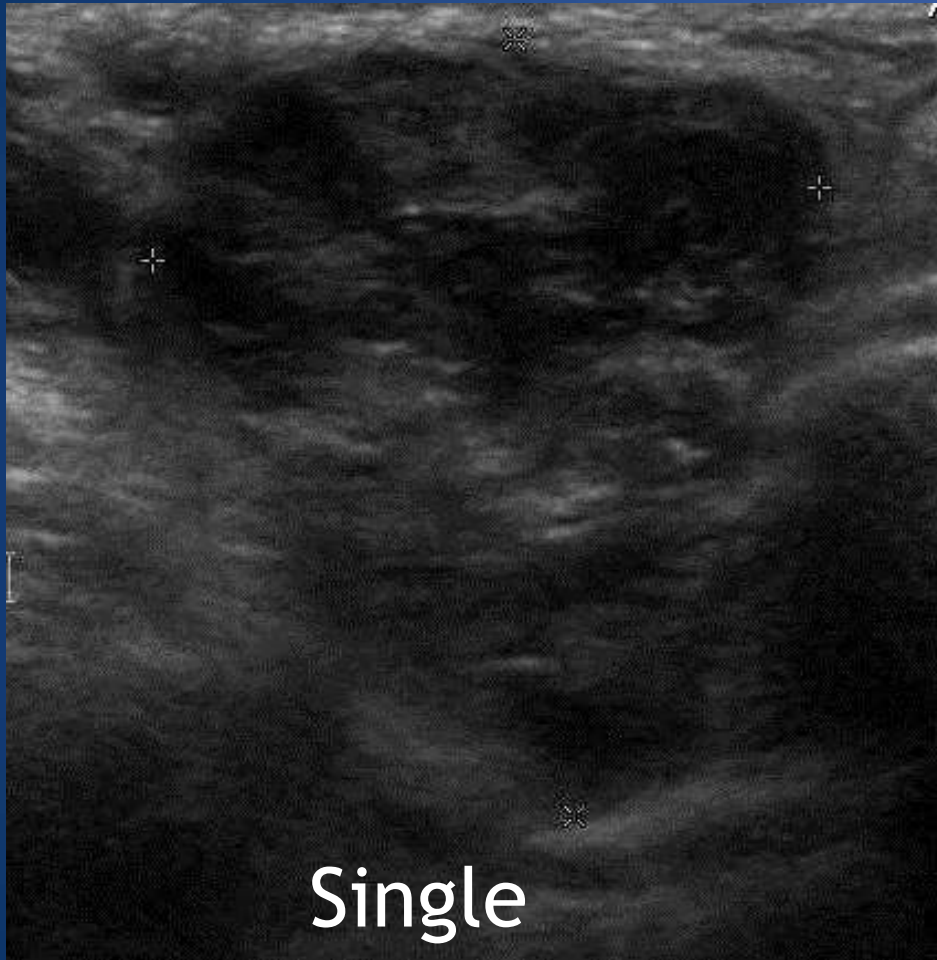


# Warthin's Tumour



Note the variable appearance of Warthin's tumour on US. In case 1 the tumour is mainly solid, but contains two small cystic areas (arrows). In case 2 the tumour is almost entirely cystic and contains internal echoes.

# Warthins Tumour



NB Male, Smoker  
Tail of parotid, Bilateral

# Pitfalls in salivary imaging

Deep lobe extent (parotid)

Atypical Facial N palsy (parotid)

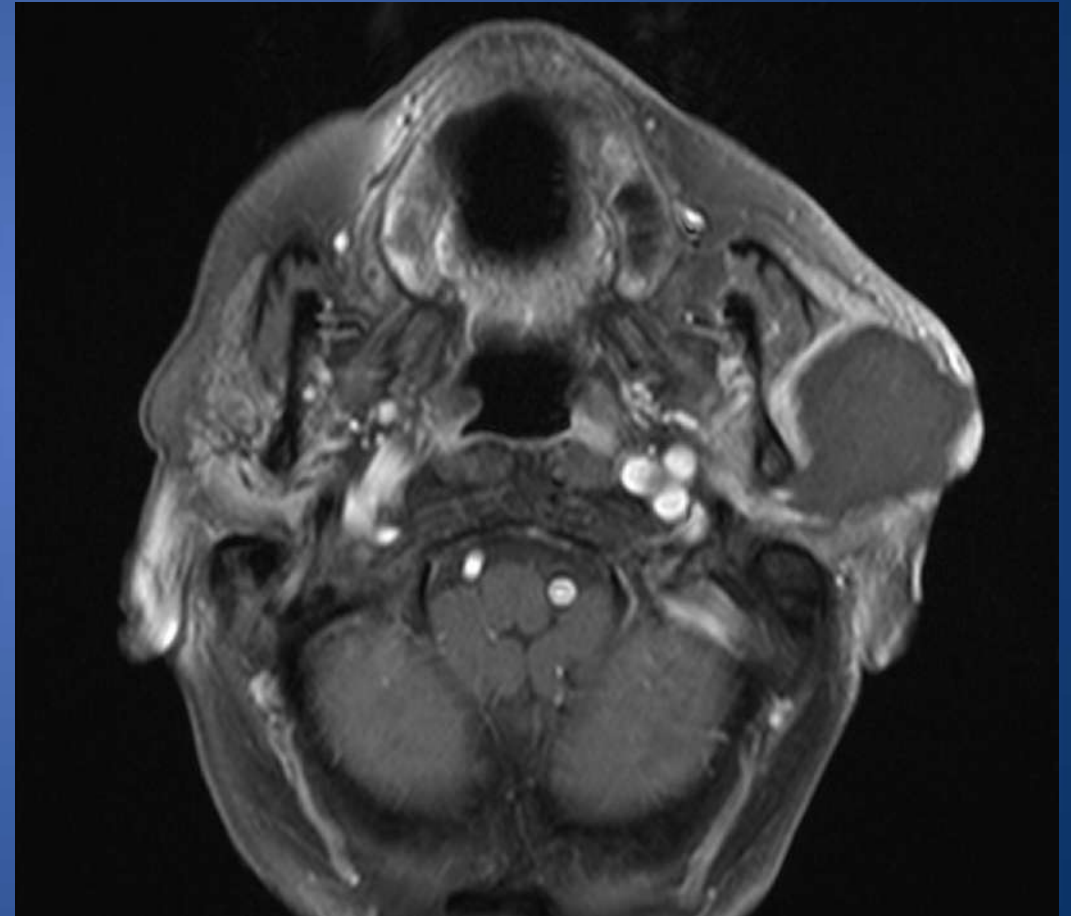
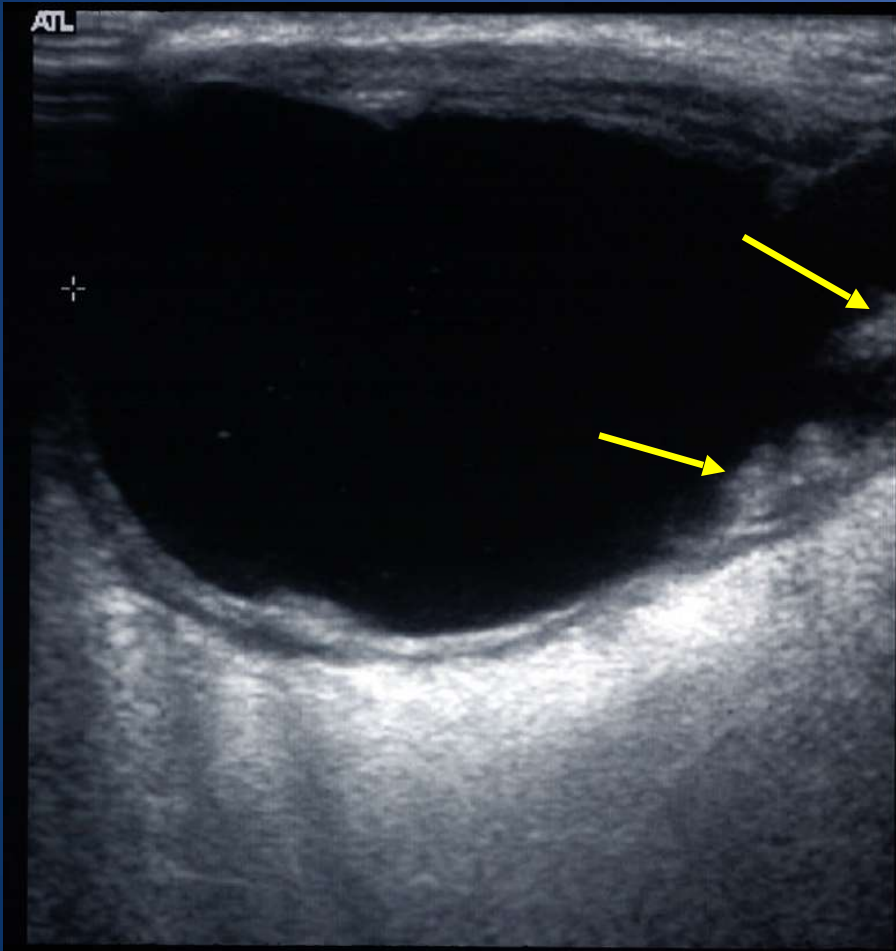
**Cystic salivary lesions**

Inflammation v tumour

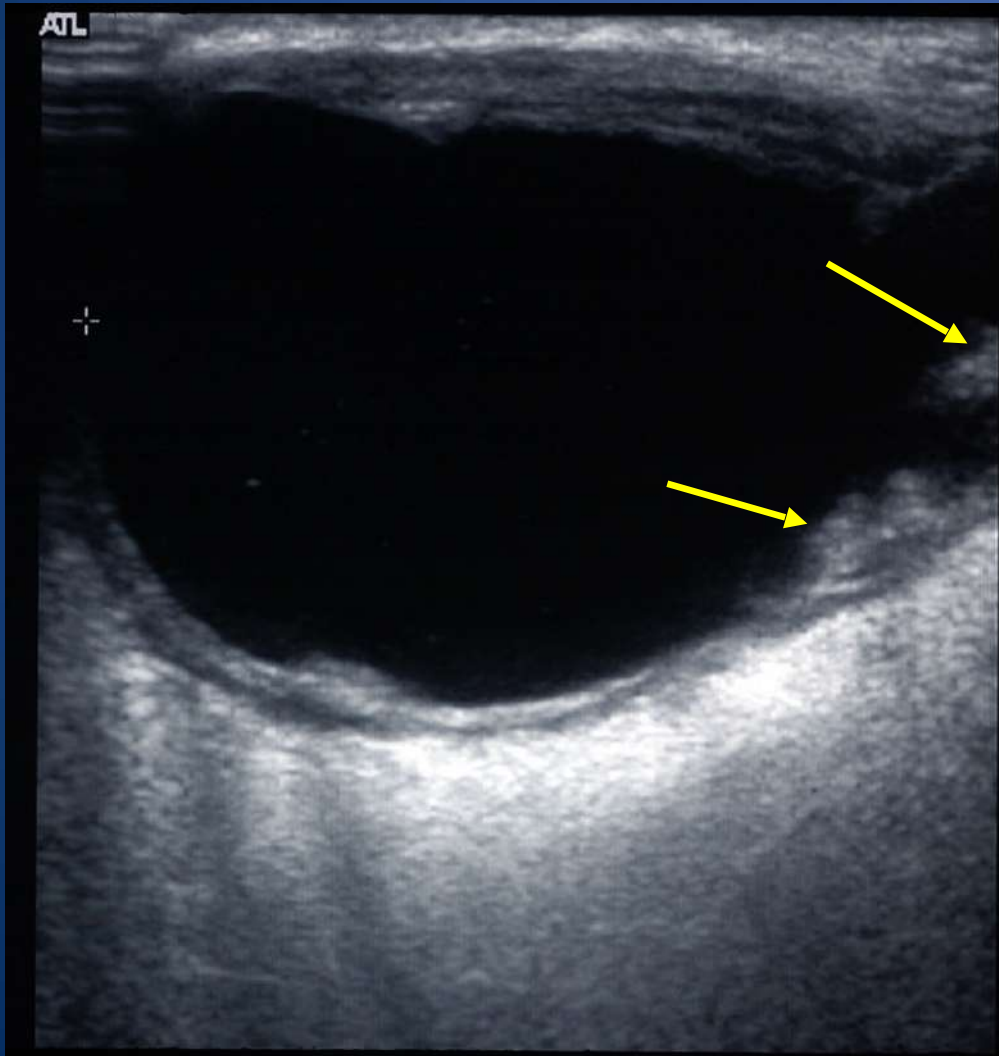
Sublingual/minor salivary tumours

Lymphoma in Sjogrens

Pitfall:  
“inflammatory” parotid cyst  
Diagnosis?



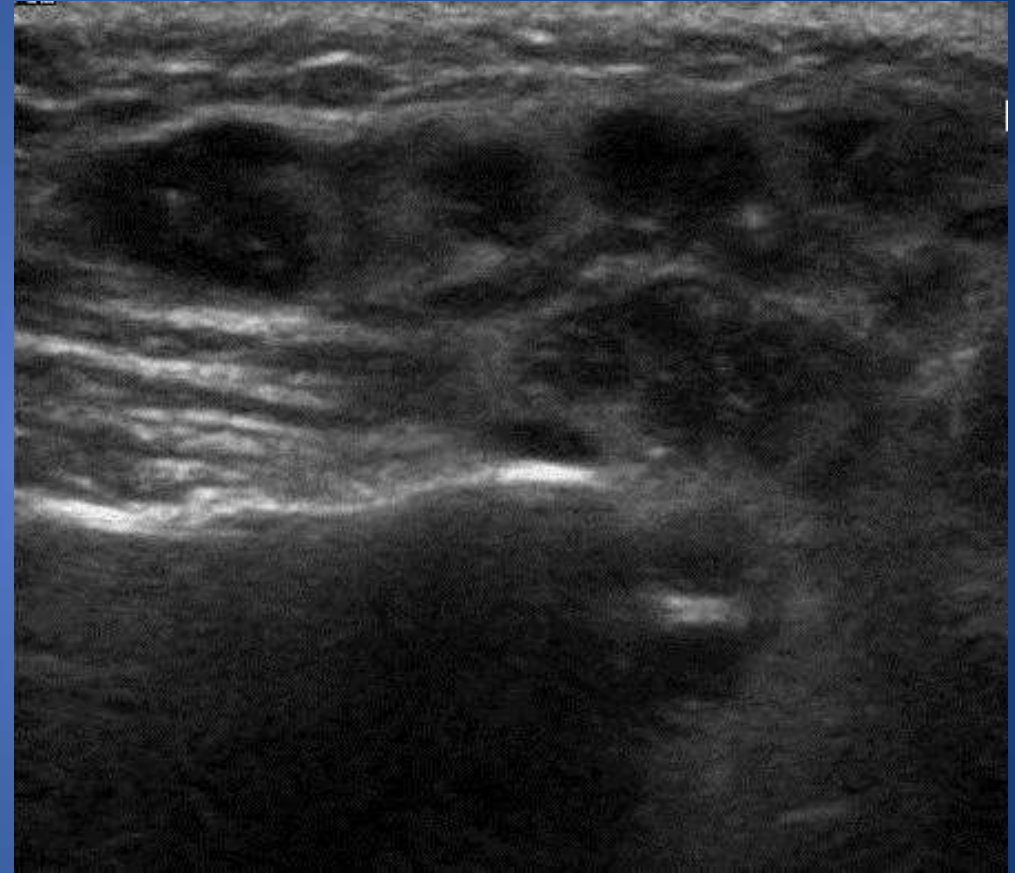
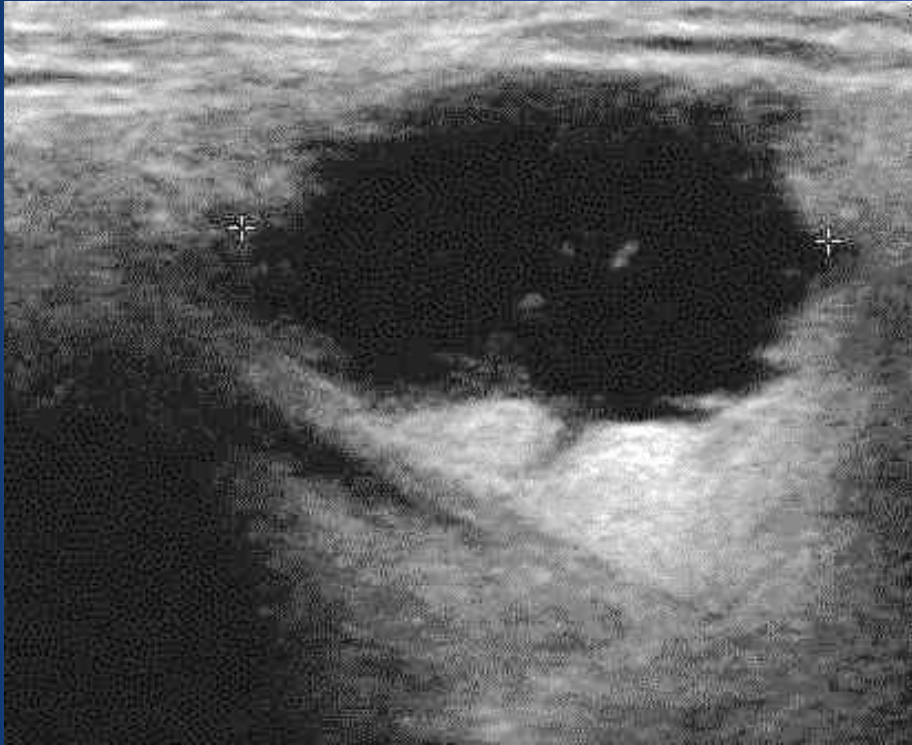# Mucoepidermoid



Coronal US image of  
a cystic parotid mass.

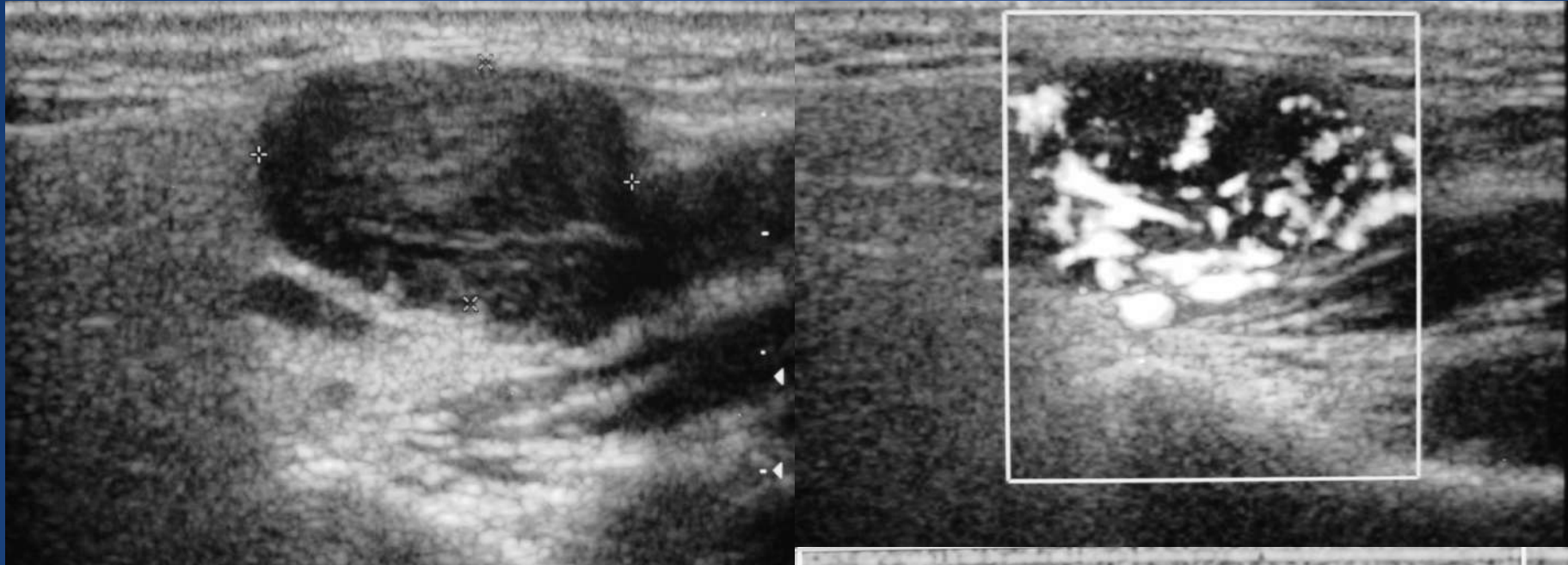
T h i n k  
mucoepidermoid

# Diagnosis? Pseudocystic mass




Remember lymphoma if pseudocystic mass  
or new mass in Pt with Sjogrens

# Parotid Lymph Node Metastases

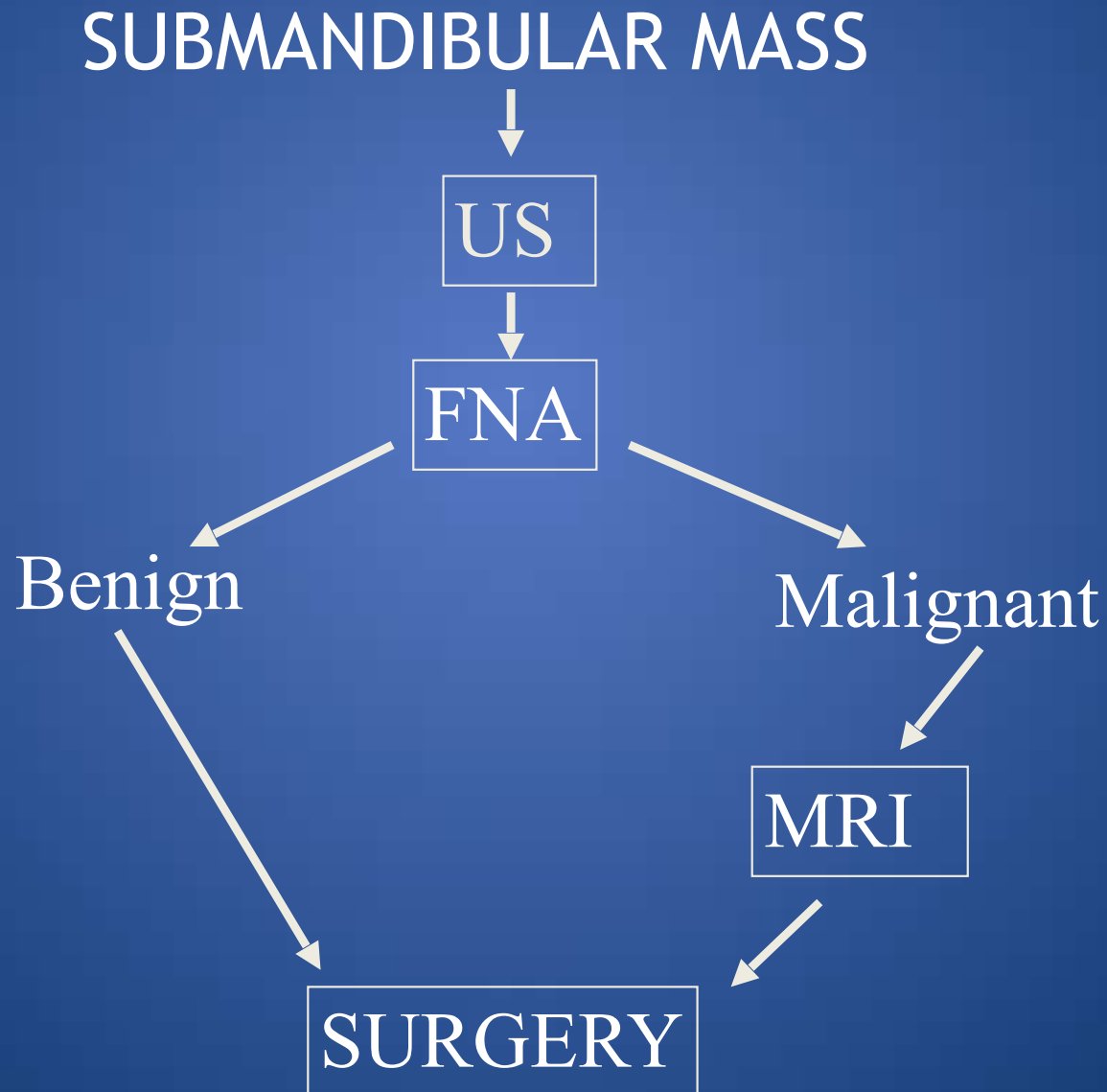


Note chaotic hypervascularity of the intraparotid lymph nodes. Known renal carcinoma, suggestive of metastases.

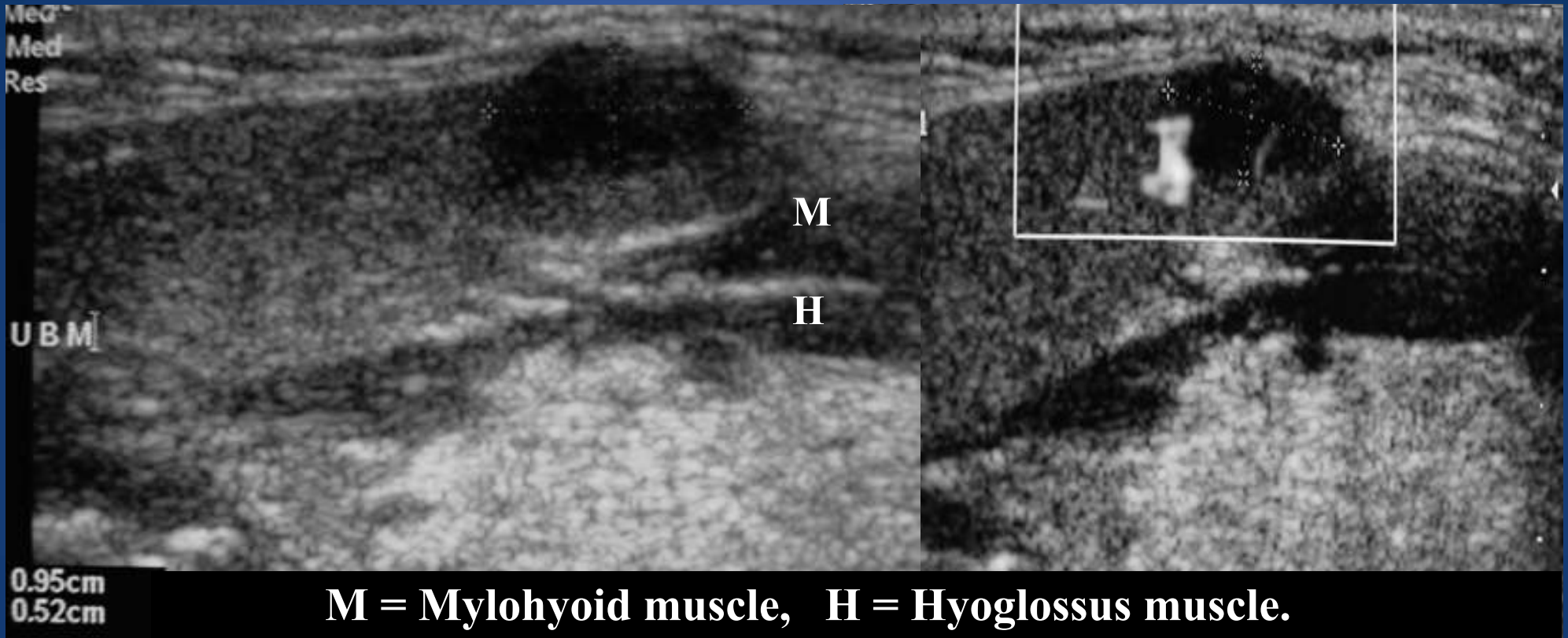
Confirmed with FNA cytology.



# Imaging Algorithm: Submandibular Mass



# Submandibular Tumour



0.5 x 0.9cm clearly visualised on US.

Adenoid cystic carcinoma on FNA and excision

# Imaging Protocol: Sublingual and Minor Salivary Glands

## MINOR SALIVARY GLANDS

- MRI is performed in all cases.
- CT may be used to demonstrate bony erosion e.g. palatal tumours.
- US may be helpful. Malignancy 50-80%
- Palate > tongue base others v rare (subglottic, sinonasal, EAC)

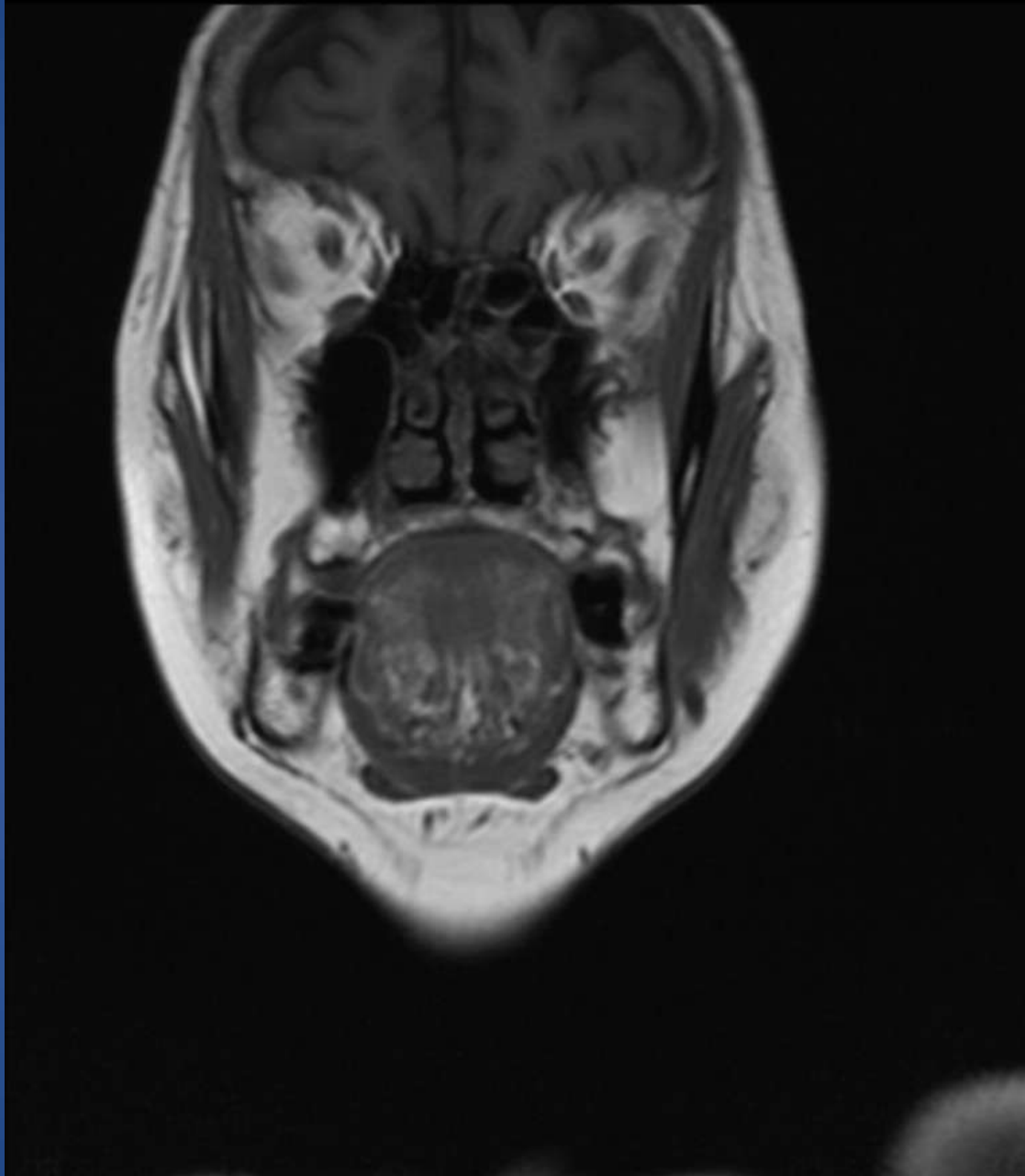
# Imaging Protocol: Sublingual and Minor Salivary Glands

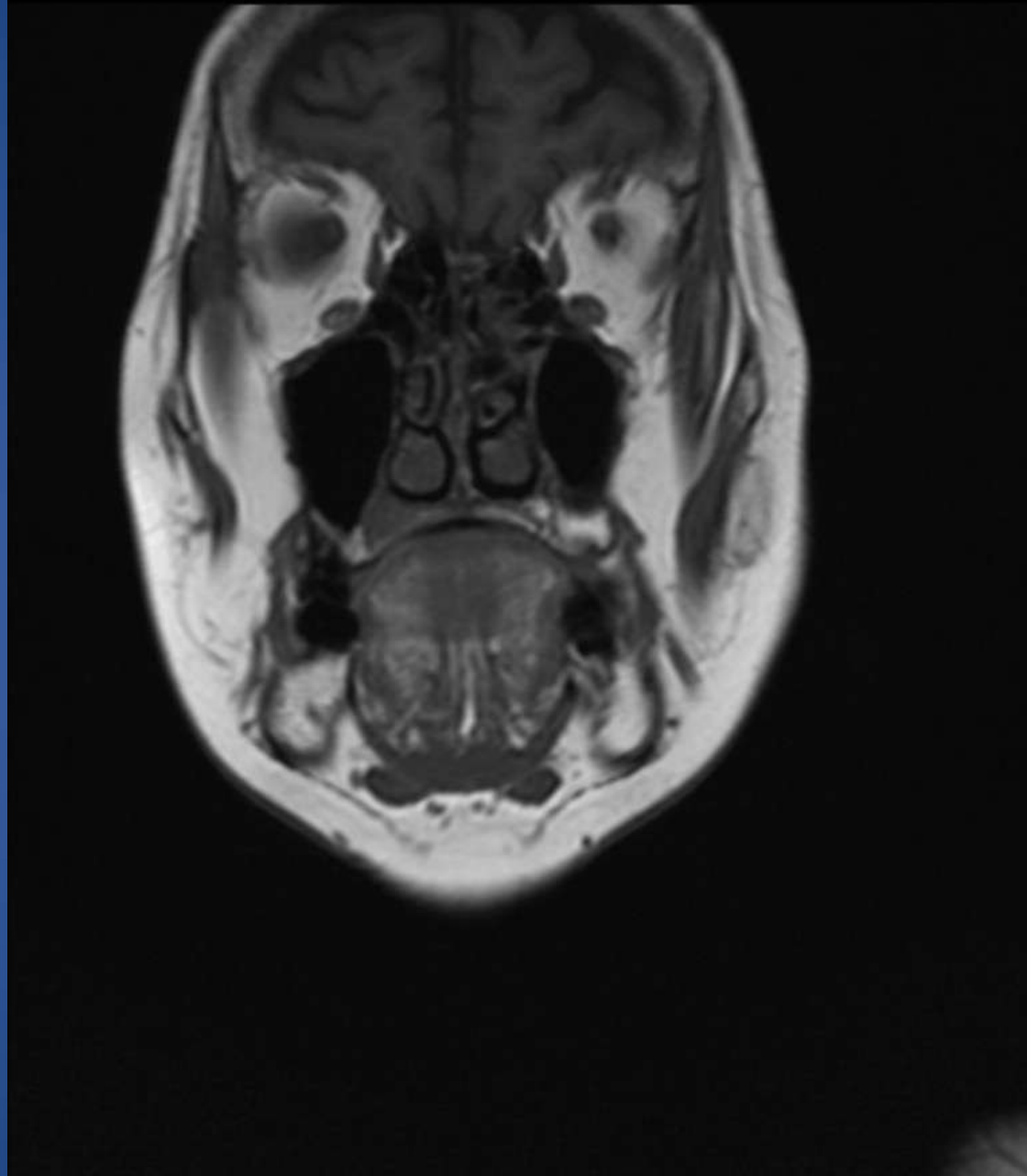
## MINOR SALIVARY GLANDS

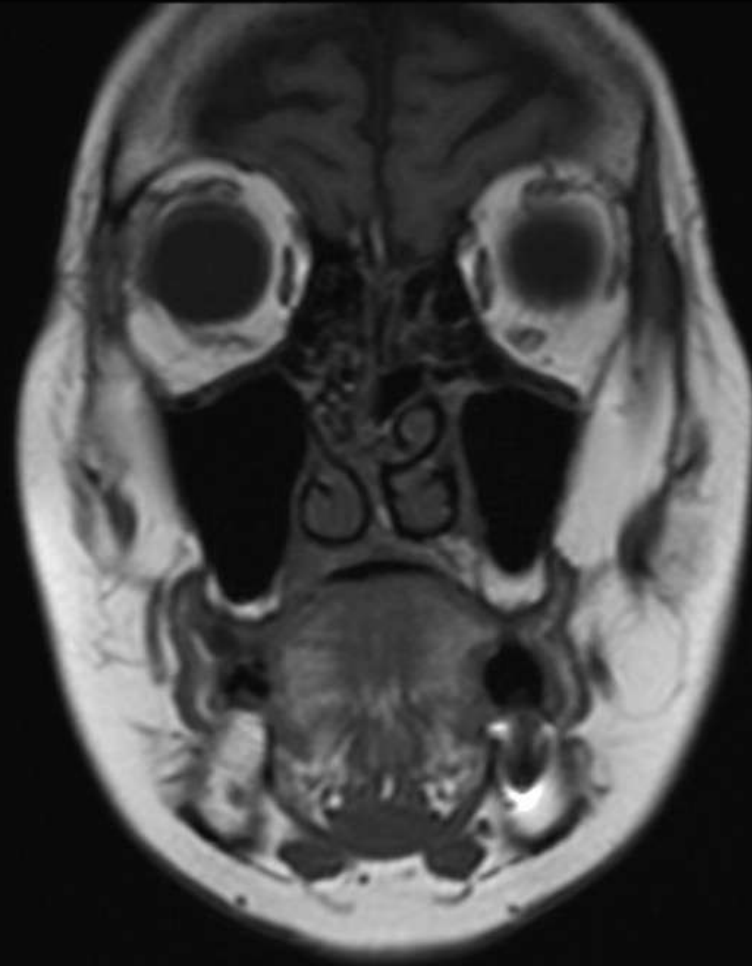
- MRI is performed in all cases.
- CT may be used to demonstrate bony erosion e.g. palatal tumours.
- **US may be helpful. Malignancy 50-80%**
- Palate > tongue base others v rare (subglottic, sinonasal, EAC)

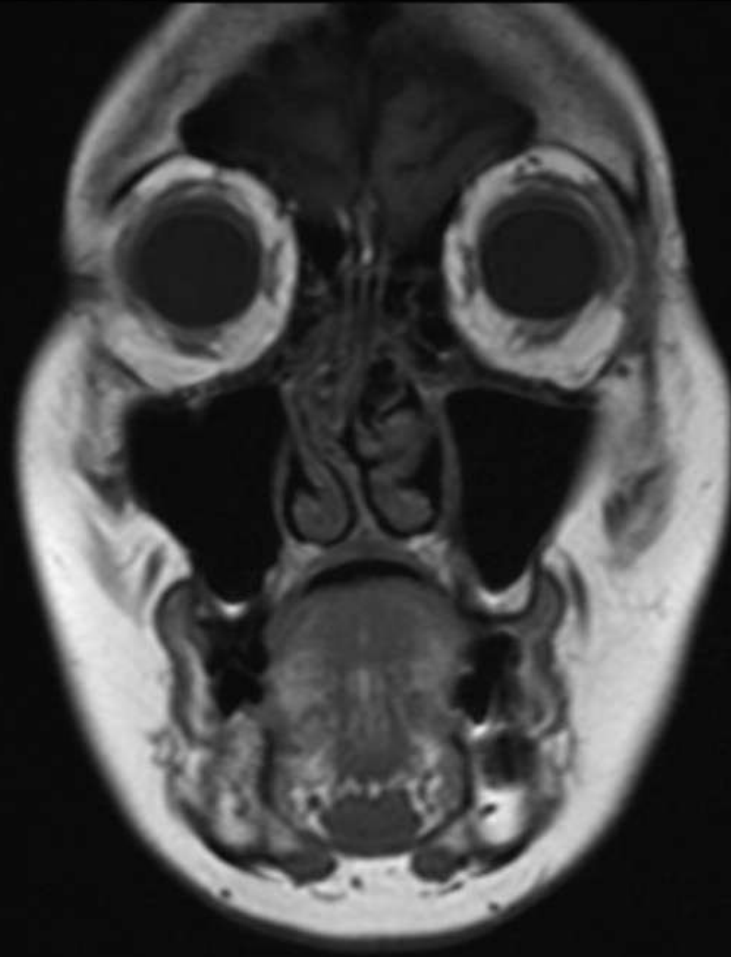
# Minor salivary tumour

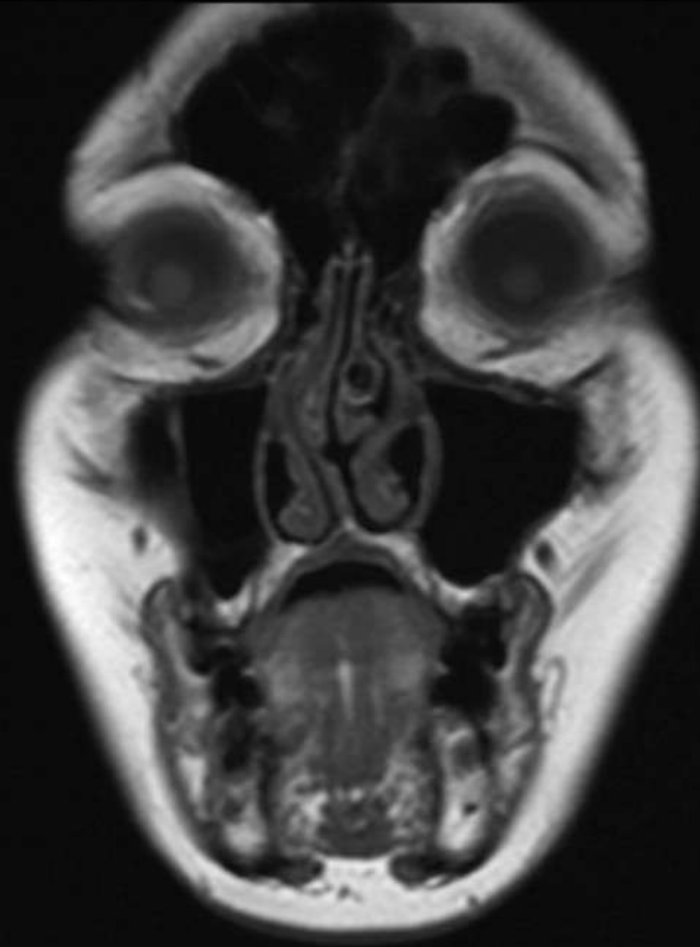
- 30 year old male
- Minute ulcer right hard palate

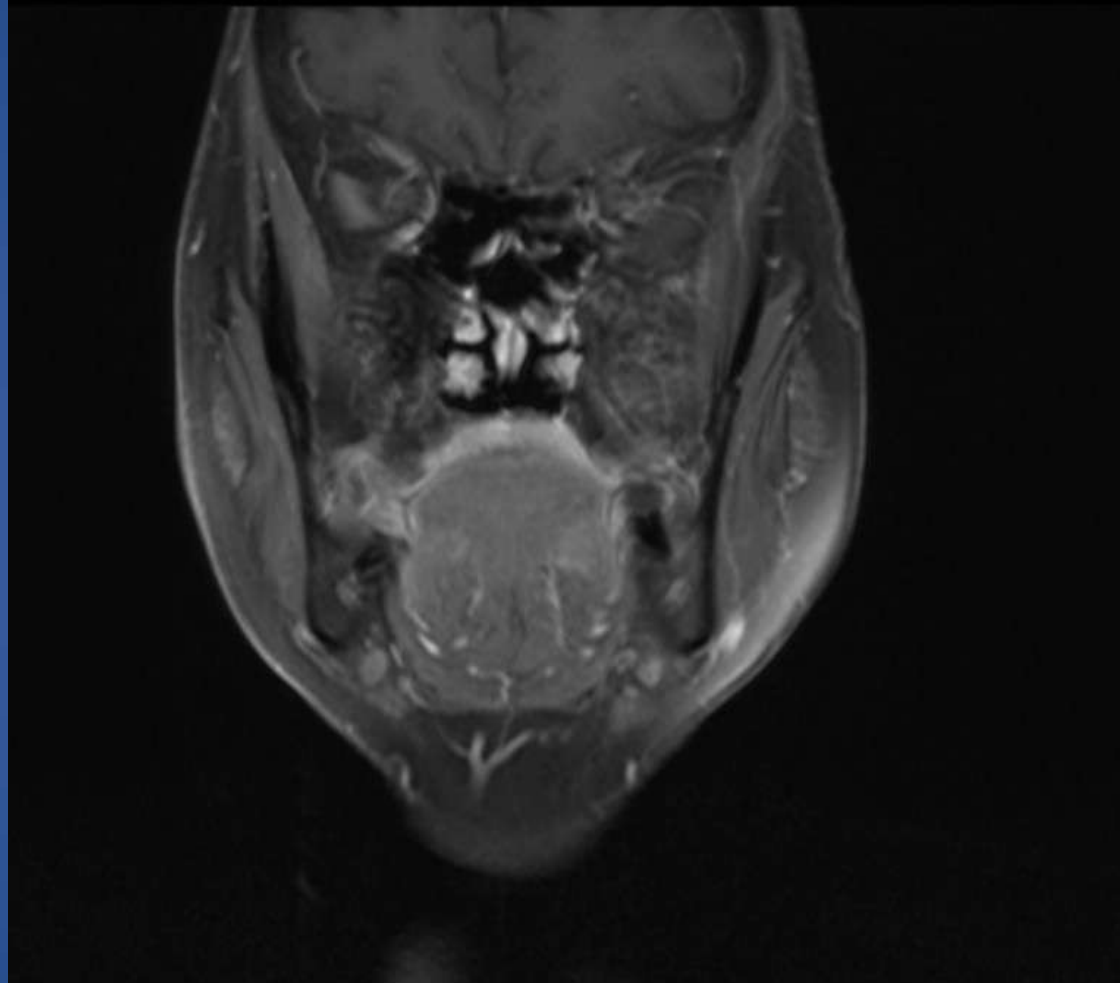


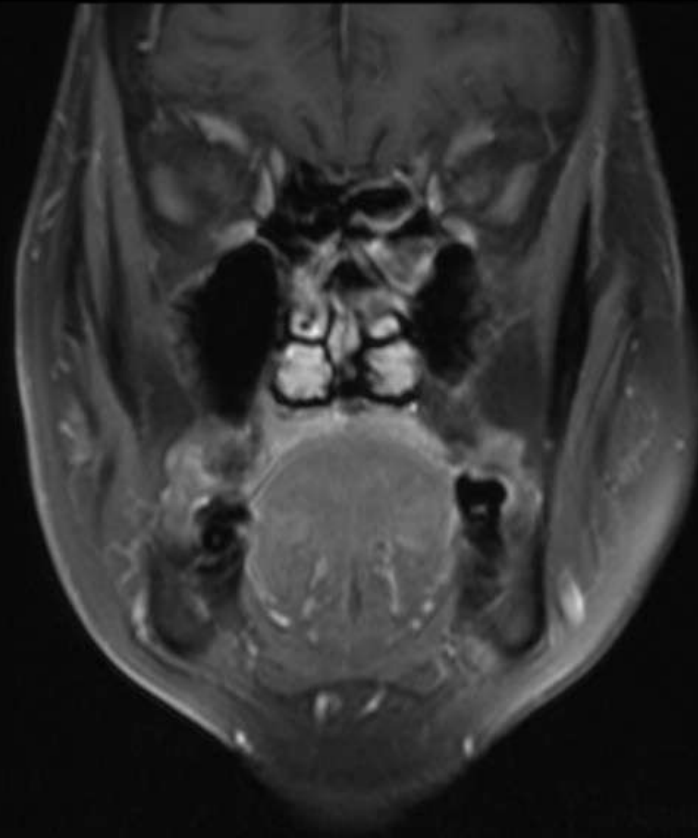

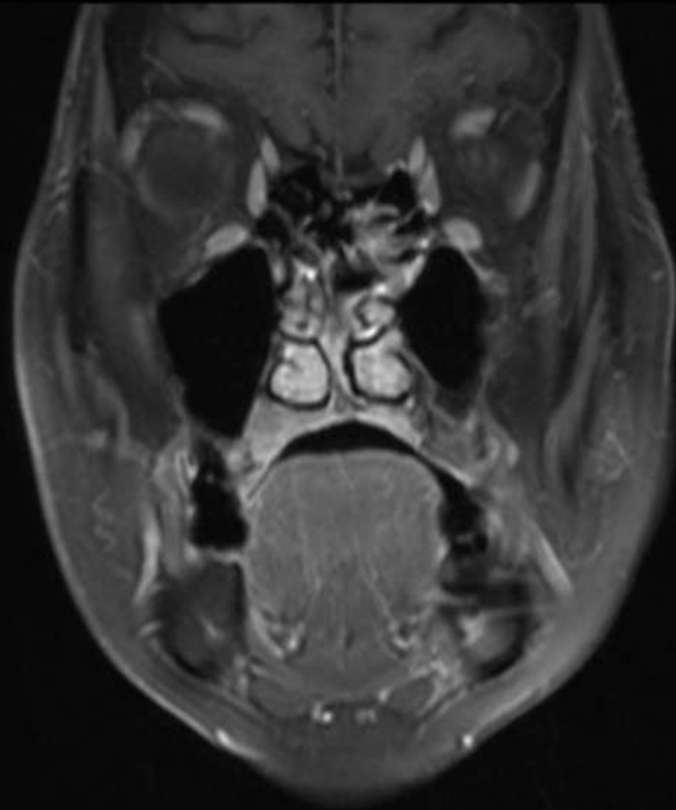


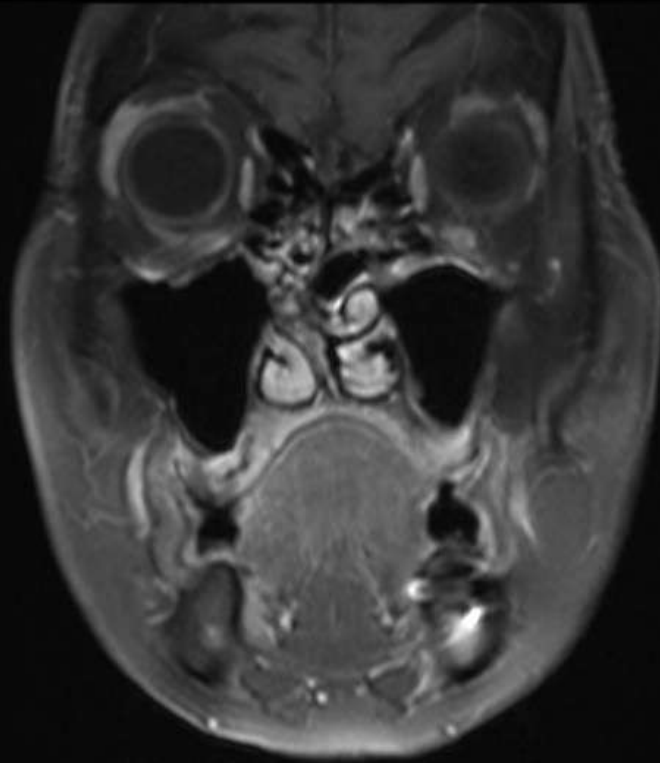




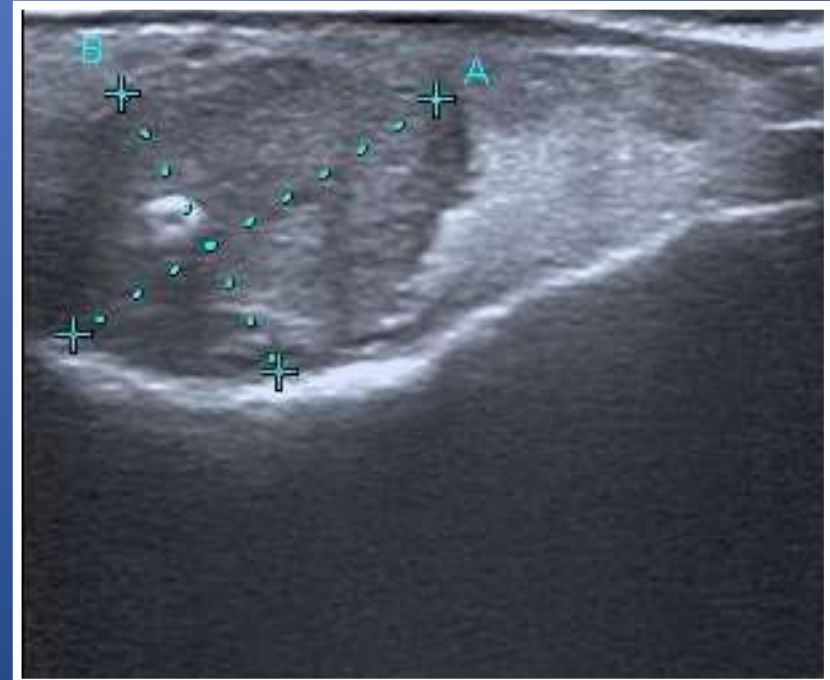
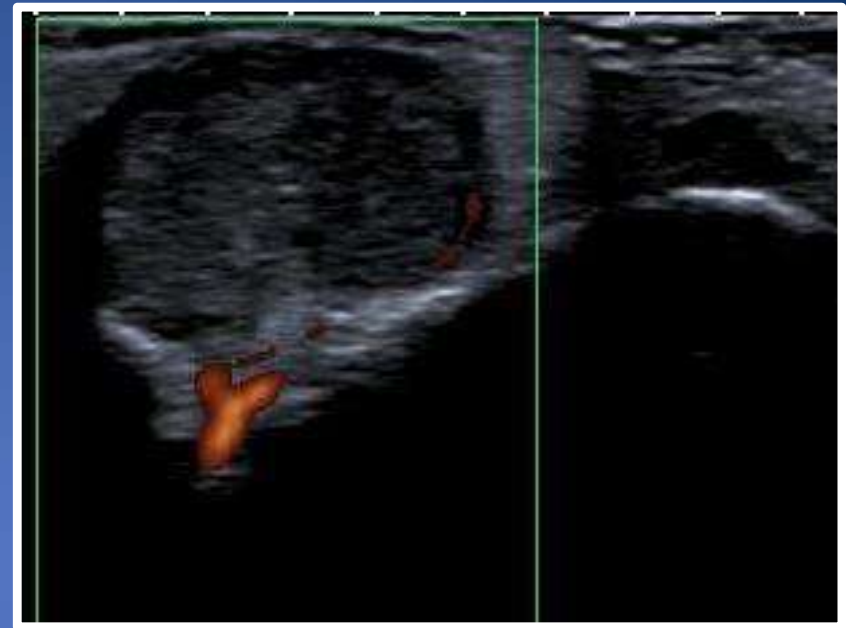

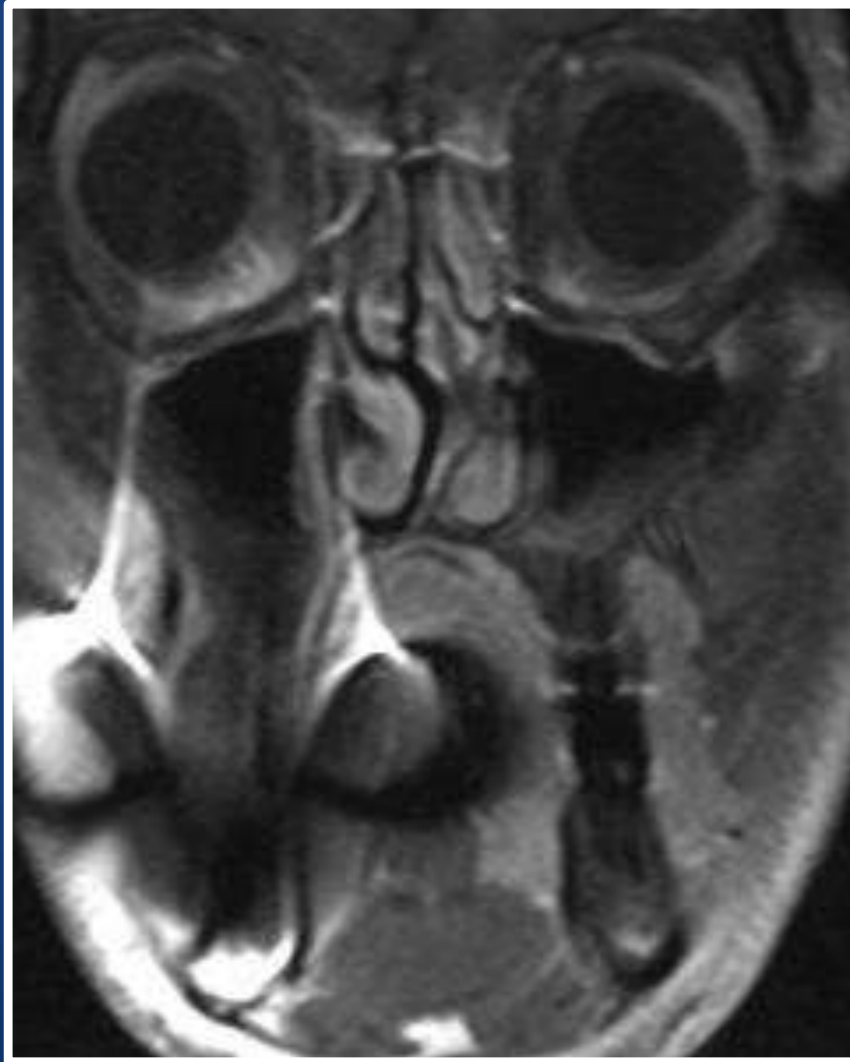


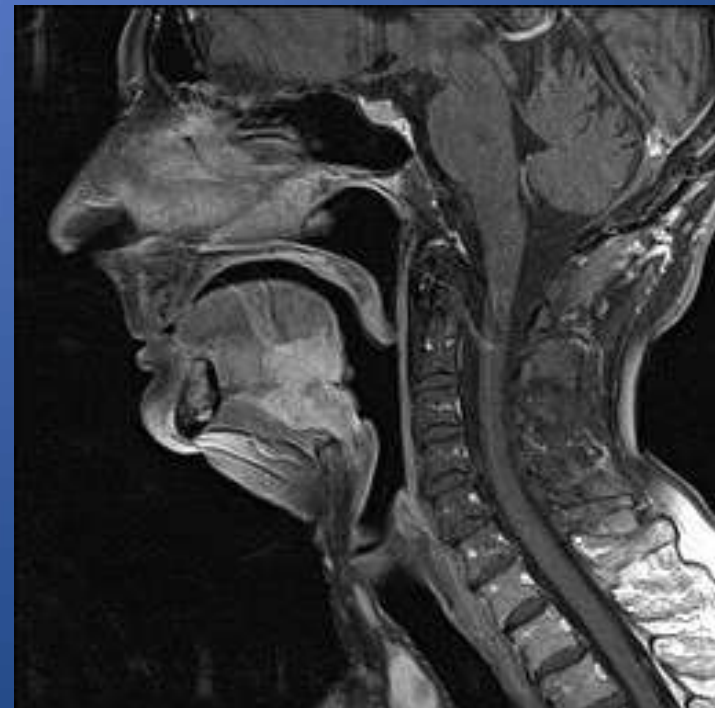
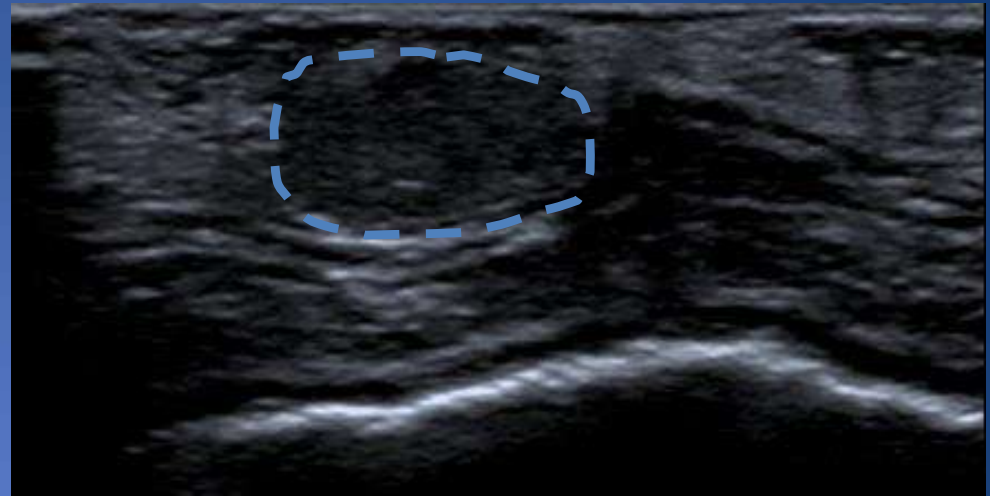


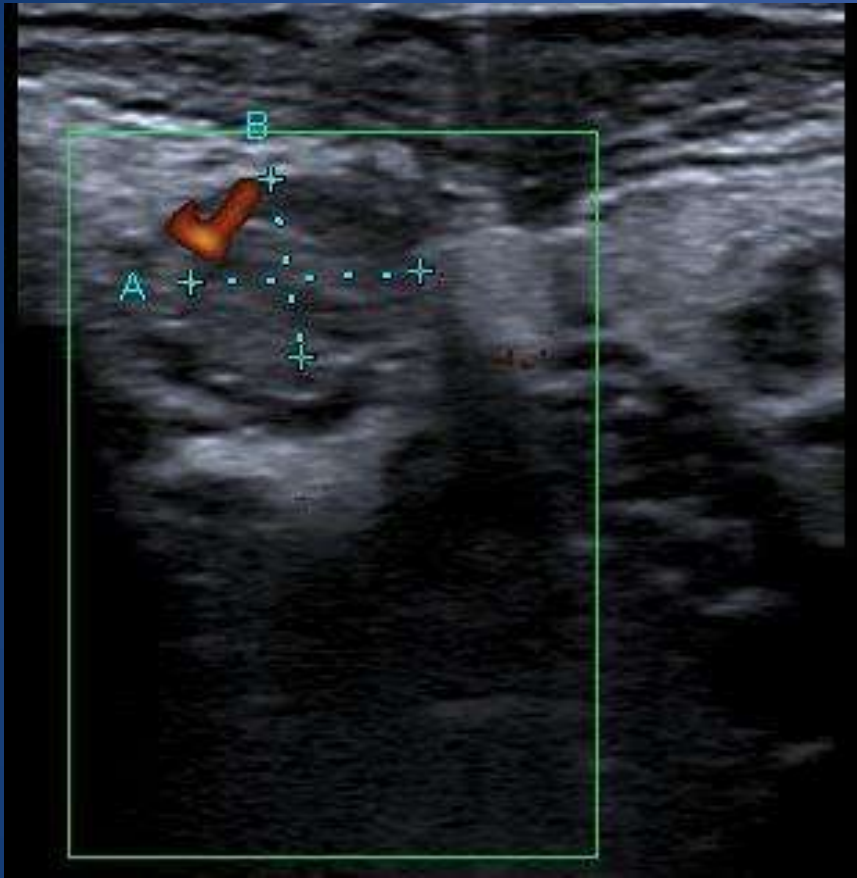

# Palatal Tumour MR v US!



# Minor salivary gland tumour



Tongue

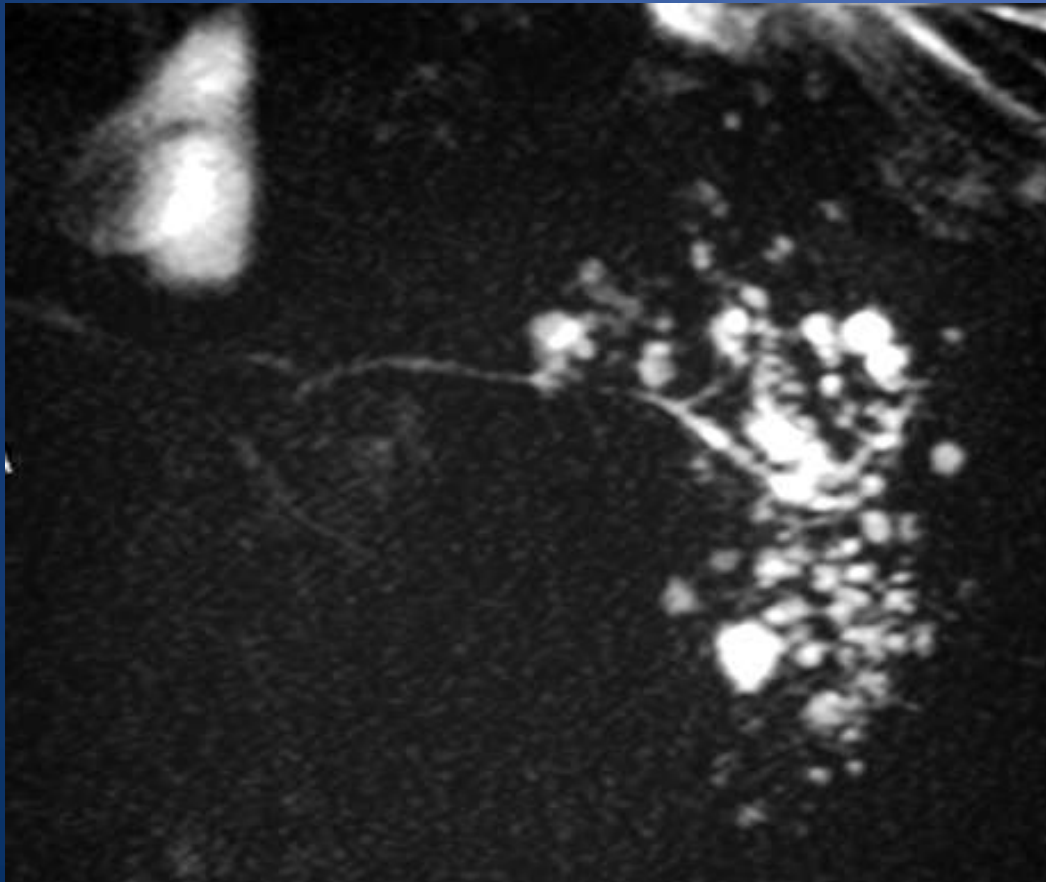
Finally

Other salivary inflammatory, infective disorders

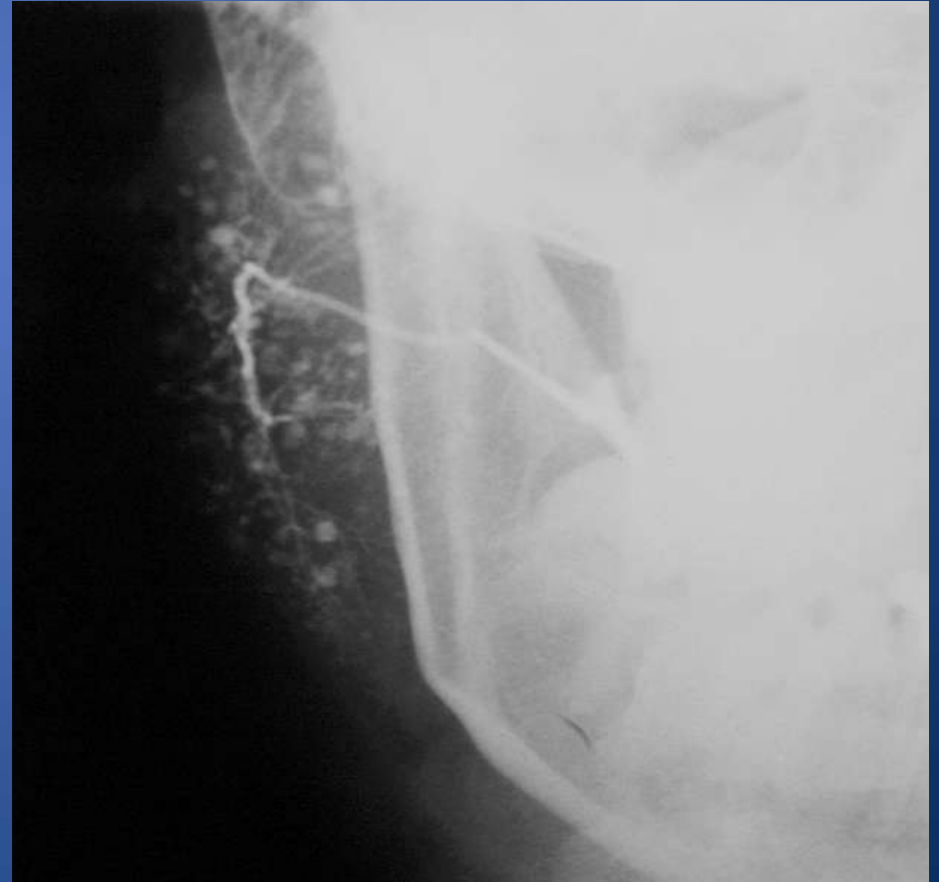


# Sjögren's Syndrome: Sialography

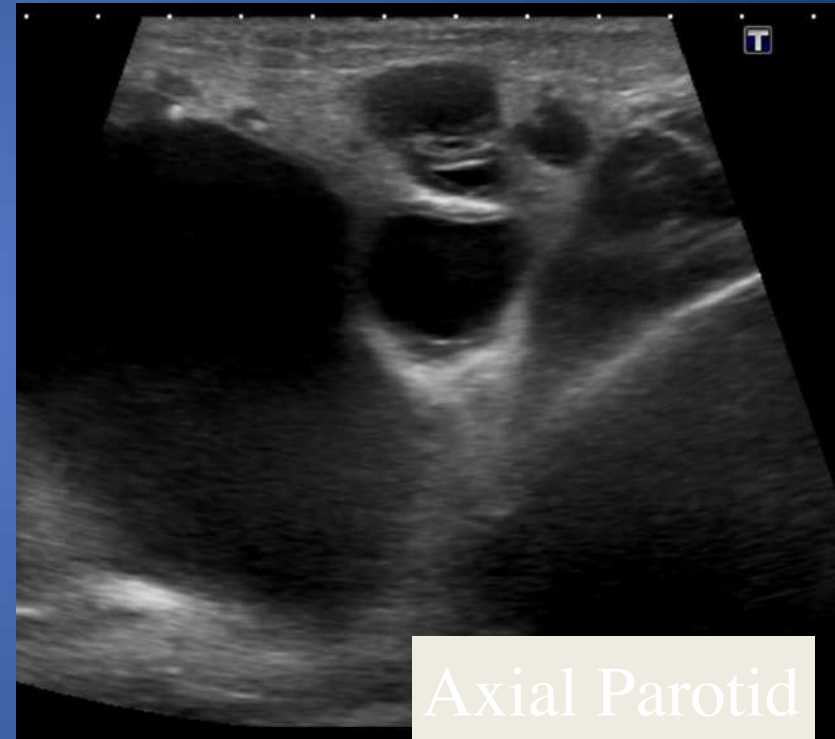
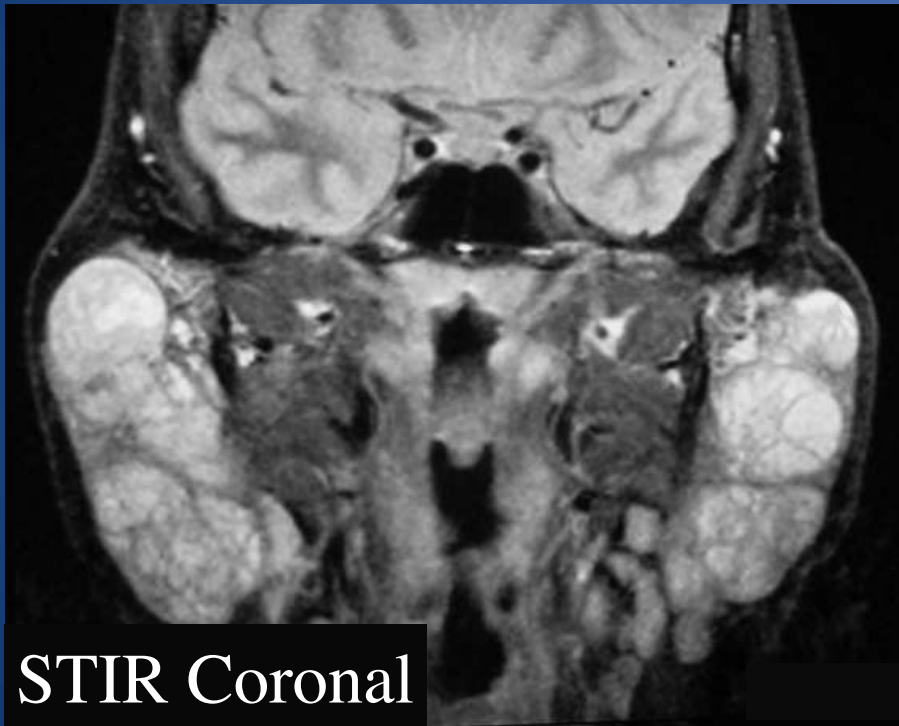
MRI Sialogram



Conventional Sialogram



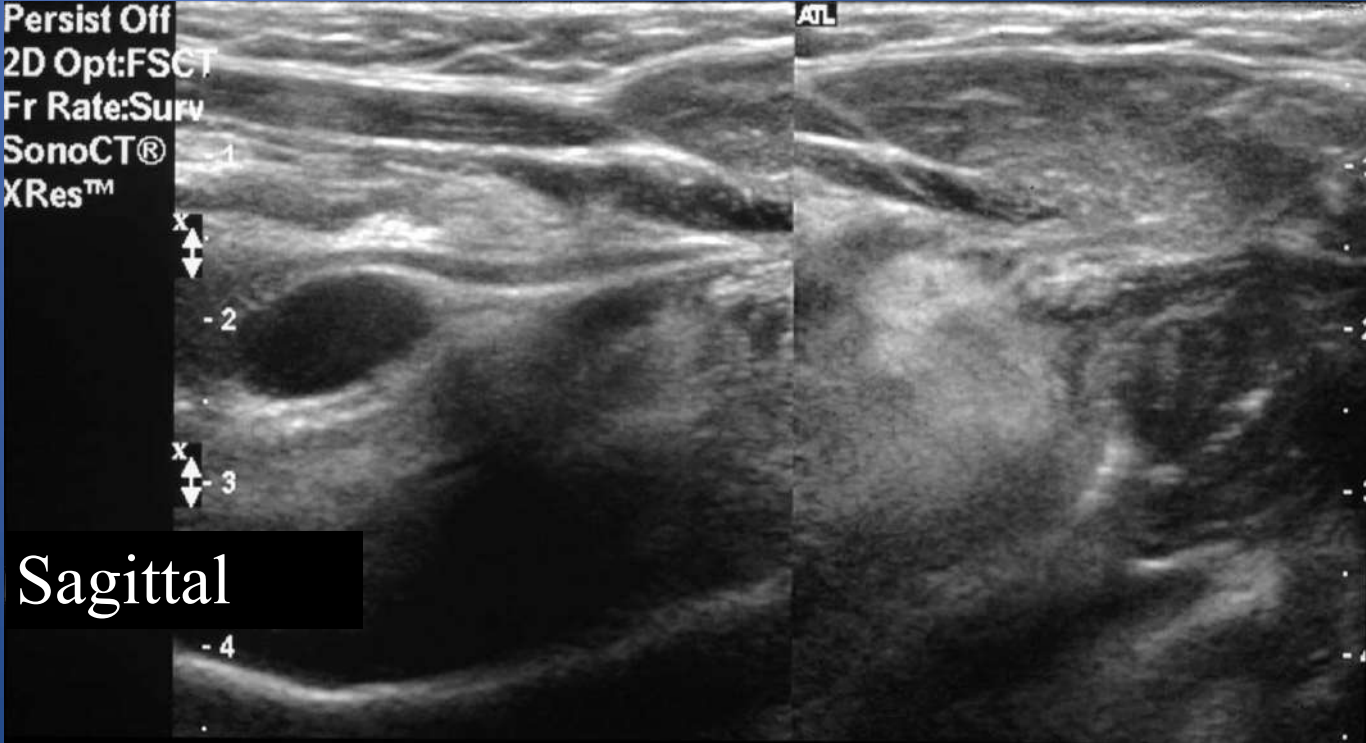
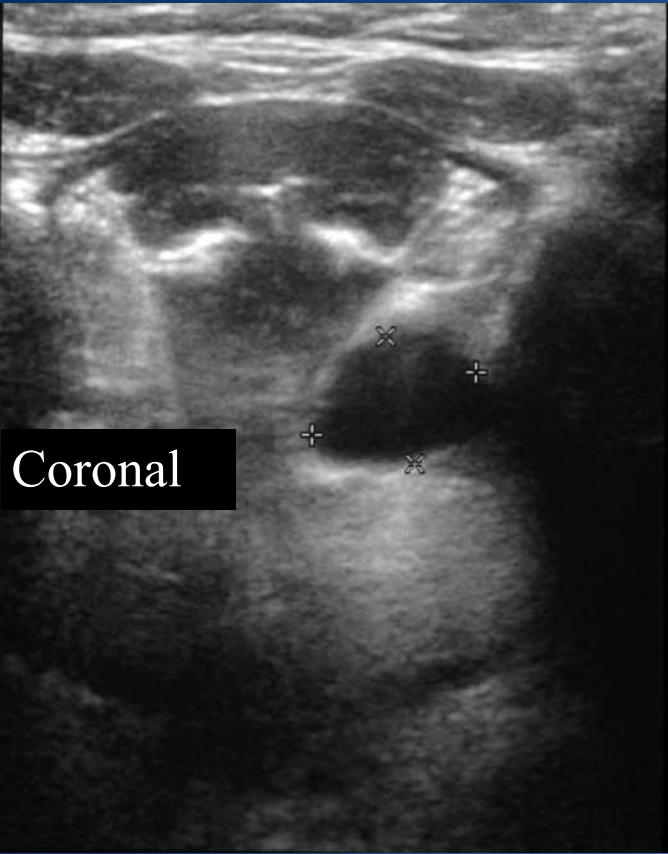
# Diagnosis?



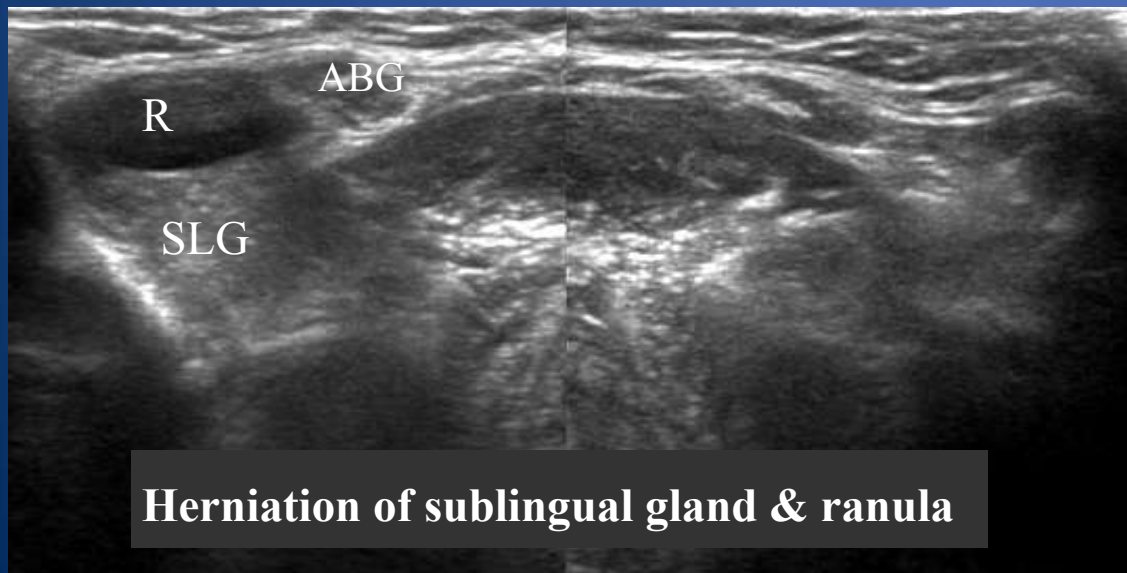
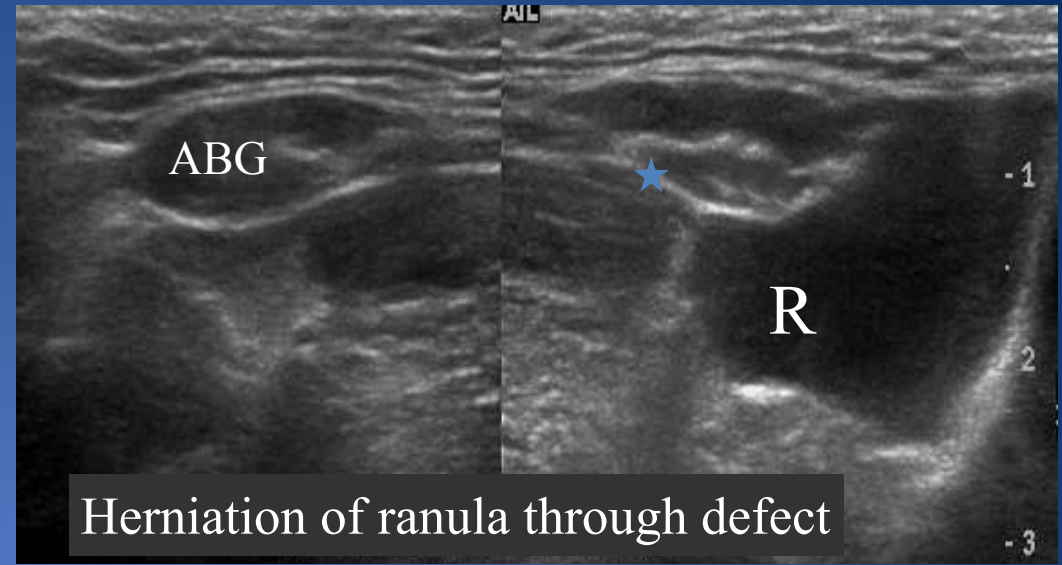
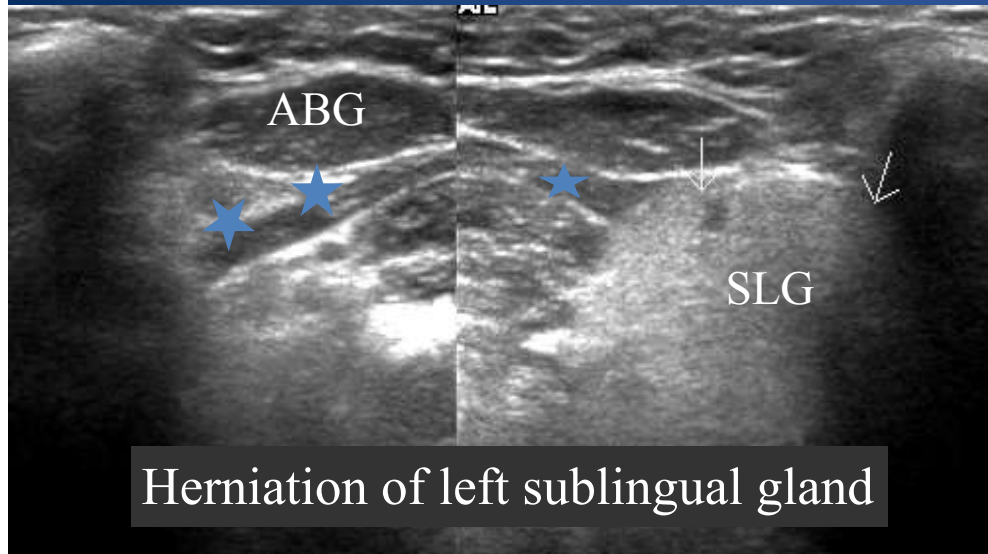
# HIV Sialopathy: Cystic Benign Lymphoepithelial Lesions (BLEL)

- Multiple bilateral or unilateral cystic & solid lesions of the parotid gland are seen in 3-6% of patients with HIV infection.
- FNA of the cystic fluid is both diagnostic and therapeutic.
- +/- associated cervical lymphadenopathy, adenoidal and tonsillar hypertrophy.

# Diagnosis? Swelling floor of mouth



# FOM: Atypical Ranula

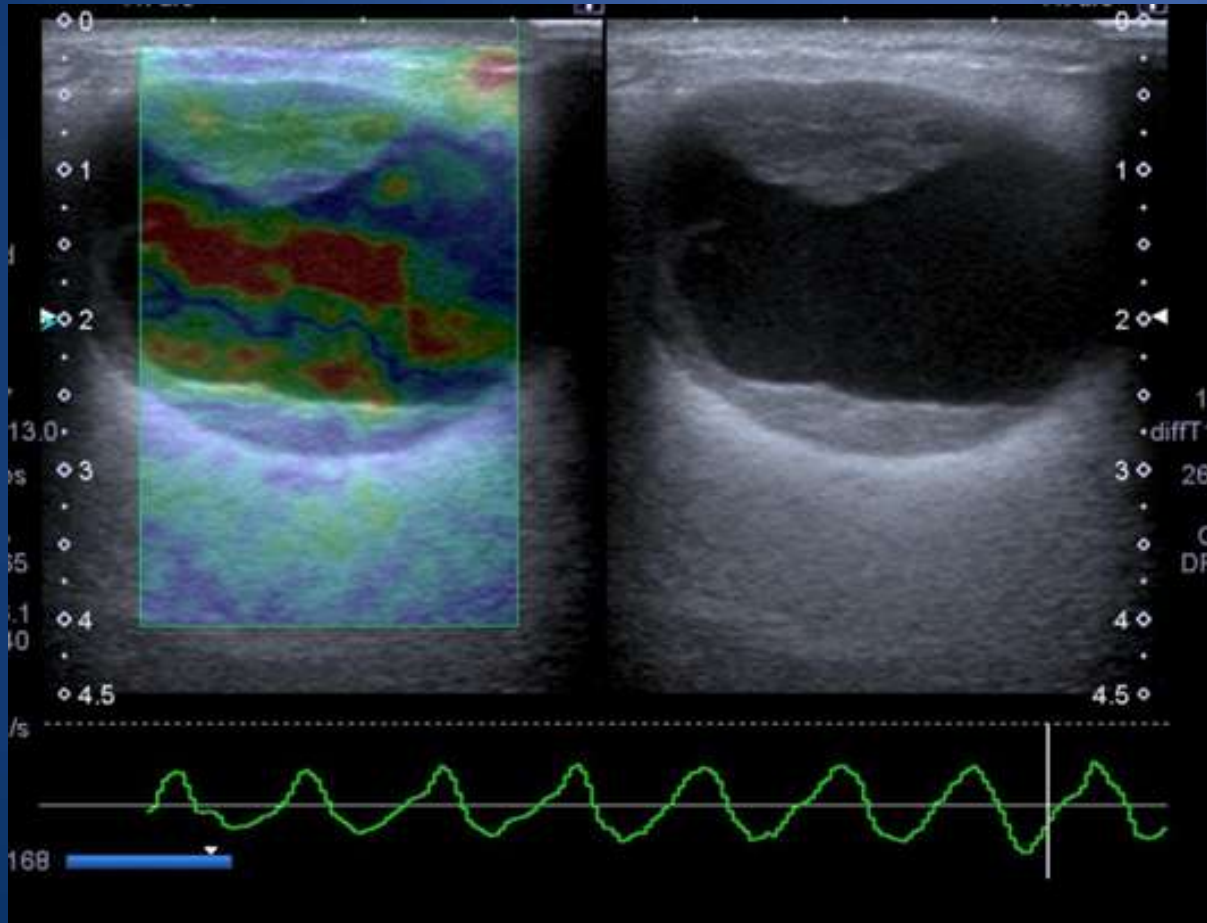


A to C coronal USS of floor of mouth

SLG = Sublingual gland,  
ABG Anterior belly of digastric, R = Ranula

★ = Mylohyoid

# Advances in salivary imaging Elastography



- Unfortunately neither strain or shear wave elastography can reliably differentiate benign from malignant.
- Malignant usually stiffer than benign but overlap

# Thankyou

